

Case Report

Sezary syndrome with pulmonary involvement: a case report

Rohit Mukherjee^{1*}, Ashwin Songara¹, Swapnil Shikha², Awadhesh P.S. Solanki³

¹Department of Respiratory Medicine, Aurobindo Medical College and PG Institute, MP, Indore, India

²Department of Medicine, RMI Hospital, Delhi, India

³Department of Psychiatry, IPGMER, Kolkata, India

Received: 07 June 2016

Revised: 09 June 2016

Accepted: 23 June 2016

*Correspondence:

Dr. Rohit Mukherjee

E-mail: drmukherjee1987@gmail.com

Copyright: © the author(s), publisher and licensee Medip Academy. This is an open-access article distributed under the terms of the Creative Commons Attribution Non-Commercial License, which permits unrestricted non-commercial use, distribution, and reproduction in any medium, provided the original work is properly cited.

ABSTRACT

Mycosis fungoides and sezary syndrome are the type of cutaneous T cell lymphoma characterized by localization of malignant T-lymphocytes in the skin at presentation. Mycosis fungoides (MF) is characterized by an epidermotropic skin infiltrate of atypical CD4-positive helper T-cell clones, and sezary syndrome (SS), is characterized by erythroderma and leukemia. Here we are presenting a case of 50 year old male who presented with extensive skin lesions along with breathlessness since 25 days and fever, was misdiagnosed as end stage sarcoidosis on CT chest, but later proved to be pulmonary involvement of sezary syndrome. The objective of our study is to describe our experience identifying lung involvement by CTCL on the basis of clinical and radiographic findings.

Keywords: Mycosis fungoides, Sezary syndrome, Lung

INTRODUCTION

Cutaneous T cell Lymphoma are the type of Non Hodgkin Lymphoma characterized by localization of malignant T cell in the skin.¹ Mycosis fungoides (MF) and sezary syndrome (SS) account for approximately 65% of Cutaneous T-Cell Lymphoma(CTCL).² Lung is the most common extranodal site of involvement.³ MF, the most frequently observed CTCL, was first described by Alibert in 1806 as a common epidermotropic lymphoma with an indolent evolution characterized by cutaneous lesions in the form of patches, plaques or skin tumours. Incidence is 0.36 per 1 lakh population and its twice more common in males.⁴

Later on, atypical lymphocytes with hyperconvoluted nuclei named sezary cells were noted in high frequency in blood of MF patients, with such patients presenting as diffuse erythroderma, identified as erythrodermic variant of MF with disseminated disease and often involving

lymph nodes and bone marrow, known as sezary syndrome.

International Society for Cutaneous Lymphomas (ISCL) established the criteria for the diagnosis of SS which included an absolute sezary count of at least 1000 cells/mm³ in the blood, demonstration of immunophenotypic abnormalities (expanded CD4+ population or loss of antigens such as CD2, CD3, CD5 or CD4) or presence of a T-cell clone in the blood. Sezary syndrome is an aggressive clinical entity associated with poor prognosis and a median survival of 2–3 years.

CASE REPORT

We report a 56 year old man with a 12 month history of multiple pruritic, papulonodular lesions of size 1 to 5 cm in diameter with well defined border, red erythematous, non tender, indurated, which covered more than 80% of the body surface area and were associated with swollen

lips and lusterless hair. He had dry cough and breathlessness usually on exertion since 2 months. Discrete generalized, movable, non tender lymphadenopathy in cervical, axillary, supraclavicular and inguinal regions, maximum size being 2 × 3 cm. He had grade 1 clubbing, pallor, generalized edema too.

His complete blood count was suggestive of anemia of chronic disease, with neuterophilia. Total serum proteins s/o hypoproteinemia with A/G reversal. Diagnostic pleural tapping was done which came out to be transudative. Chest – Xray P/ A view was done which suggested bilateral heterogenous patchy opacities & macronodular shadows with bilateral minimal pleural effusion (R>L) (Figure 1).

CT chest (Figure 2) was performed suggestive of multiple irregular centrilobular nodules seen scattered in both lung segments, random in distribution, bilateral reticulonodular infiltrates. Patchy areas of consolidation seen in right middle lobe. Extensive discrete enlarged lymph nodes seen in pretracheal, hilar and both axillary regions. Minimum B/I Pleural Effusion noted.

The differentials of lymphoma, end stage sarcoidosis, tuberculosis and fungal infection was kept on the basis of CT Chest. Serum ACE levels were marginally raised. Thereafter an axillary lymph node excision biopsy and HPE was done which suggested lymph Nodes architecture effaced and replaced by mixed population of mixed lymphocytes, histocytes, immunoblast like cells with vesicular nuclei and prominent nucleoli. Infiltration of capsule and pericapsular tissue by tumour cells, on the basis of which a diagnosis of Non Hodgkin Lymphoma was kept. Histopathology slide as follows (Figure 3).



Figure 2: CT chest.

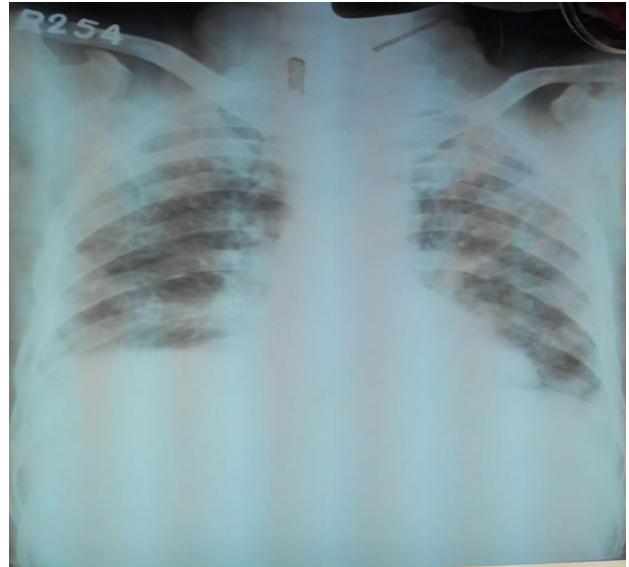


Figure 1: Chest x ray (P/A view).

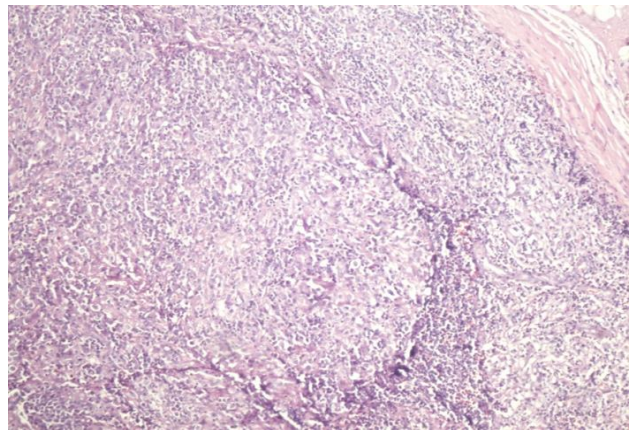


Figure 3: HPE slide.

Clinically patient presented with diffuse erythema , multiple nodular lesions of varying sizes covering more than 80% BSA (Figure 4).

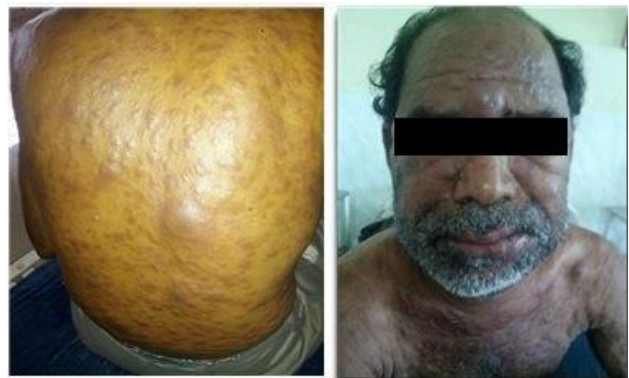

Figure 4: Back, face and chest of patient showing nodular lesions.

Skin biopsy was performed and sent for HPE which showed diffuse lymphoid infiltrates involving the full thickness of epidermis and extending to the subcutaneous dermis. These lymphocyte aggregates composed of small- to intermediate-sized lymphocytes with irregular nuclei expressing CD3/CD4/CD5. Flow cytometry suggested an abnormal cutaneous T-cell population expressing CD2/CD3/CD4/CD5 with a loss of CD7 and CD26 expression. Flow-cytometric immunophenotyping for blood also suggested the same T cell population. The blood work up suggestive of lymphocyte count of 4600 with sezary cells 1000/mm³ and a CD4/CD8 ratio of 20:1. HTLV-1 detection was negative. The diagnosis of sezary syndrome with pulmonary involvement was made. The TNM staging of our case was T4N3M1B1 with clinical stage IVb which engraved poor prognosis.

DISCUSSION

Mycosis fungoides also known as Alibert-Bazin syndrome is the most common form of cutaneous T-cell lymphoma. It generally affects the skin, but may progress internally over time. Symptoms include rash, tumors, skin lesions, and itchy skin. Cause is yet unknown but addition in chromosome in 7 and 17 and deletions in 9 and 10 may sometimes be found. Patients with classical MF progress from patch stage to plaque stage and finally to tumor stage. Most common age of presentation is 45-60 yrs. Median duration from onset of skin lesions to diagnosis is 4-6 years. In our patient it took an aggressive course in 1 year.

Early patch stage has variably sized erythematous fine scaly lesions (mild pruritus) and the commonly involved sites are buttocks, covered sites of trunk and limbs. Plaque stage is related with infiltrated reddish brown scaly plaques that may gradually enlarge and may have an annular, polycyclic or horse-shoe shaped configuration.

Tumour stage associated with combination of patches, plaques and nodules with ulceration. Extra cutaneous features include regional lymph nodes and visceral involvement subsequently.

Sezary syndrome is a variant of mycosis fungoides, occurring in about 5% of cases, in which the patient has generalised erythroderma. Sezary cells CD4+T lymphocytes with a highly convoluted and bizarre morphological appearance with a grooved or cerebriform nucleus seen in tissue and blood. It is characterised by erythroderma, pruritus, generalised lymphadenopathy and hepatosplenomegaly. It occurs most frequently in middle-aged males. Sezary syndrome is defined by erythroderma and leukemic variant of mycosis fungoides characterized with edematous skin, lymphadenopathy, palmar and/or plantar hyperkeratosis, alopecia, nail dystrophy, ectropion, hepatosplenomegaly.

Diagnostic Criteria given by ISCL for erythroderma and evidence of a T cell clone in the blood plus any one of the following:

1. >1000 Sezary cells/mm³
2. CD4 : CD8 ratio of >10 : 1
3. Increased percentage (40%) of CD4 cells with an abnormal phenotype.

Complications may include infections, high-output cardiac failure, anaemia of chronic disorders, edema, secondary malignancies, skin cancer including melanoma and colon cancer.

The prognosis of patients with MF/SS is based on the extent of disease at presentation. Overall prognosis is poor with median survival of 2-4 yrs.⁵ The presence of lymphadenopathy and involvement of peripheral blood and viscera, increase in likelihood with worsening cutaneous involvement which define poor prognostic groups.

A common cause of death during the tumor phase is sepsis from *Pseudomonas aeruginosa* or *Staphylococcus aureus* caused by chronic skin infection with *Staphylococcus* species and subsequent systemic infections.⁶

CONCLUSION

Pneumonia and lung involvement by CTCL are relatively rare but portend poor survival. Thus, patients with CTCL should be evaluated thoroughly with thoracic imaging when they experience respiratory symptoms.

Funding: No funding sources

Conflict of interest: None declared

Ethical approval: Not required

REFERENCES

1. Girardi M, Heald PW, Wilson LD. The pathogenesis of mycosis fungoides. N Engl J Med. 2004;350:1978–88.
2. Willemze R, Jaffe ES, Burg G. WHO-EORTC classification for cutaneous lymphomas. Blood. 2005;105: 3768–85.
3. Weinstock MA, Gardstein B. Twenty-year trends in the reported incidence of mycosis fungoides and associated mortality. Am J Public Health. 1999;89:1240–4.
4. Rubin DL, Blank N. Rapid pulmonary dissemination in mycosis fungoides simulating pneumonia. A case report and review of the literature. Cancer. 1985;56:649–51.
5. Scarisbrick JJ, Whittaker S, Evans AV. Prognostic significance of tumour burden in the blood of patients with erythrodermic primary cutaneous T cell lymphoma. Blood. 2001;97:624.

6. Zackheim HS, Amin S, Kashani-Saket M. Prognosis in cutaneous T cell lymphoma by skin stage: Long term survival in 489 patients. *J Am Acad Dermatol.* 1999;40:418–25.

Cite this article as: Mukherjee R, Songara A, Shikha S, Solanki APS. Sezary syndrome with pulmonary involvement: a case report. *Int J Sci Rep* 2016;2(7):168-71.