

## Case Report

# Schwanomma arising from mental nerve: a rare entity

Ratna Priya\*, Nitish Virmani, J. P. Dabholkar

Department of ENT, Seth G.S. Medical College and K.E.M Hospital, Mumbai, Maharashtra, India

**Received:** 09 August 2016

**Accepted:** 26 August 2016

**\*Correspondence:**

Dr. Ratna Priya

E-mail: [ratnapriya01@gmail.com](mailto:ratnapriya01@gmail.com)

**Copyright:** © the author(s), publisher and licensee Medip Academy. This is an open-access article distributed under the terms of the Creative Commons Attribution Non-Commercial License, which permits unrestricted non-commercial use, distribution, and reproduction in any medium, provided the original work is properly cited.

### ABSTRACT

Schwannomas or neurilemmomas are benign tumors of the nerve sheath that are single, well encapsulated, benign and arise from the perineural schwann cells. They may arise either in central or peripheral nerves. Approximately 25–45% of all schwannomas are present in the head and neck region. The overall incidence of intra-oral schwannomas is 1% with most common site being tongue followed by buccal mucosa and lastly lip and gingival. Here we present a case report of lower lip schwannoma arising from mental nerve. On physical examination, a smooth globular swelling was present in the lower lip on right side, 2 cm × 3 cm in size and of firm, non-tender in character with regular margins. The patient underwent surgery and the lesion was excised intraorally with sublabial incision. Final pathological diagnosis was made as “schwannoma.” The patient has been following up for 6 months and there is no evidence of any recurrence. High index of suspicion is required and Schwannoma should be considered as a differential diagnosis in oral cavity benign lesions. The final diagnosis is based on histopathology report and immunohistochemical analysis. The treatment of these tumors is complete resection. The prognosis of such cases is extremely good, without any recurrence.

**Keywords:** Schwannoma, Lower lip, Mental nerve, Complete excision, Histopathology, Prognosis

### INTRODUCTION

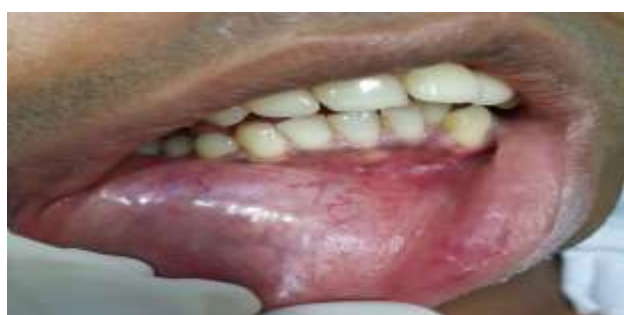Schwannomas or neurilemmomas are benign tumors of the nerve sheath that are single, well encapsulated, benign and arise from the perineural schwann cells. They may arise either in central or peripheral nerves. Approximately 25–45% of all schwannomas are present in the head and neck region. In the head and neck region, the tumor mostly appears in the tongue. Lower lip is an extremely rare site with only a few similar cases reported in the literature. Here we present a case report of schwannoma of the lower lip arising from mental nerve.

### CASE REPORT

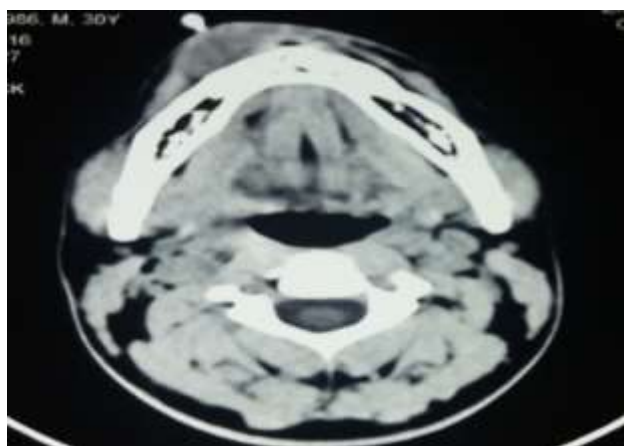A 30 year male was admitted to the department of Otorhinolaryngology with a painless lesion located in the lower lip on the right side as presented in Figure 1.

Clinical history revealed that the lesion was present since 3 months and was not associated with any pain or bleeding or any history of prior trauma. On physical examination, a smooth globular swelling was present in the lower lip on right side, 2 cm × 3 cm in size and of firm, non-tender in character with regular margins extending anteriorly up to canine and posteriorly up to first pre molar. CT revealed a fairly well defined lesion in the sublabial region measuring about 1.5 cm × 3 cm × 2.3 cm with multiple tiny vascular channels within on arterial phase and becoming homogeneously enhancing on delayed phase with no obvious calcification or haemorrhage within the lesion as shown in Figure 2. Also there was no associated destruction of bone and the overlying buccal mucosa was intact. FNAC was suggestive of neurogenic tumour. The differential diagnosis consisted of minor salivary gland tumour, fibroma, neurofibroma and mucocoele. Laboratory

investigations were within normal limits. The patient underwent surgery and the lesion was excised intraorally with sublabial incision as given in Figure 3. Tumour was dissected all around and complete excision was done. As seen in Figure 4. The postoperative course was uneventful. Histopathology was suggestive of encapsulated cellular mesenchymal tumour consisting of spindle cells with a uniform cellular appearance (Antoni A pattern) throughout the tumour without hypocellular areas (Antoni B pattern). The tumour cells were arranged in palisaded fashion (Verocay bodies) as in Figure 5. Final pathological diagnosis was made as “schwannoma.” Post operatively, he developed decreased sensation in the distribution of mental nerve which gradually recovered over a period of six weeks. The patient has been recurrence-free at six months of follow up.



**Figure 1: Patient presenting with lower lip swelling.**

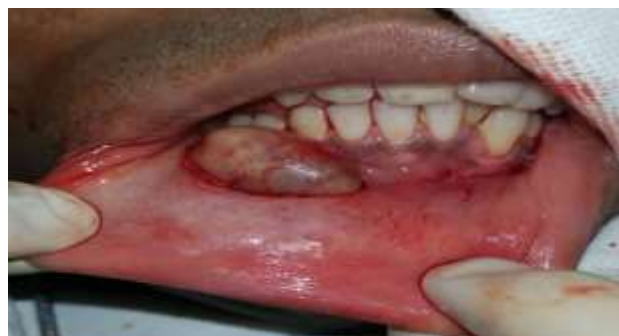

**Figure 2: CT revealed a fairly well defined lesion in the sublabial region with multiple tiny vascular channels with no obvious calcification or haemorrhage.**

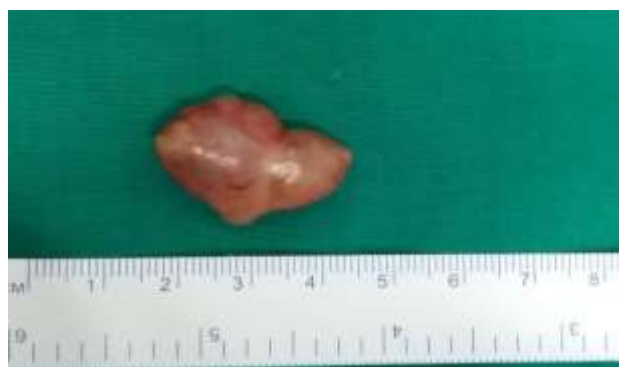## DISCUSSION

Schwannomas or neurilemmomas are rare neurogenic tumours of the peripheral nerves, arising from the Schwann cells. It was first described by Verocay in 1910. The underlying etiology is not known. Schwannomas mostly present as asymptomatic solitary nodules, with no gender predilection. Approximately 25–45% of all schwannomas are present in the head and neck region.<sup>1</sup> In the head and neck region, the tumor mostly appears in the

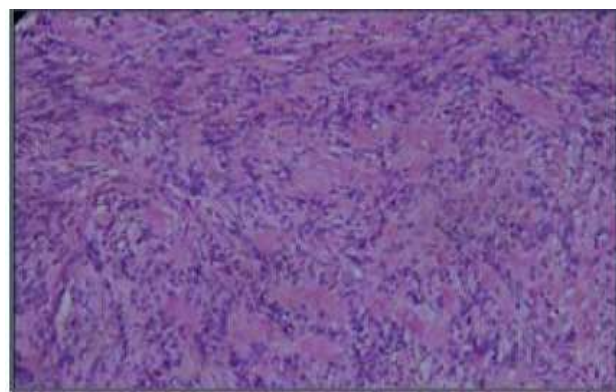
tongue. Tumour can be less likely in the palate, floor of the mouth, gingiva, buccal mucosa and parotid gland as well.<sup>2</sup> Lower lip is an extremely rare site with only a few similar cases reported in the literature.<sup>3</sup>



**Figure 3: Intraoperative picture depicting intraoral excision.**



**Figure 4: Complete excision of mass.**



**Figure 5: Histopathological picture depicting schwann cell nuclei in Antoni A tissue forming Verocay bodies.**

The age at onset varies between 20-50 years; though lately the presence of lingual schwannomas has been described in children between 10-13 years of age.<sup>4</sup>

Schwannomas do not arise from cranial nerves I and II as they lack schwann cells.<sup>1</sup> They usually arise from both peripheral and intracranial parts of cranial nerves in head and neck region. The eighth nerve is the most common intracranial site whereas peripheral cranial nerve

schwannomas are mostly found in parapharyngeal space of the neck and in soft tissues such as tongue, buccal mucosa, palate and gingival.<sup>5</sup> In parapharyngeal space, the most commonly involved nerves are the vagus and the cervical sympathetic chain.<sup>6</sup>

Das gupta et al first described schwannoma of the lip in 1969.<sup>7</sup> Since then only a few number of schwannoma cases of the lip have been reported.<sup>2</sup> The overall incidence of intraoral schwannomas is 1% with most common site being tongue followed by buccal mucosa and lastly lip and gingival.<sup>2,3</sup>

These are slow-growing and asymptomatic, and the differential diagnosis may include neuromas, neurofibromas, granular cell myoblastoma, neuro-epitheliomas, fibromas or adenomas.<sup>8</sup> The tumor may mostly manifest as a painless mass or swelling developing over several years. Mostly it is asymptomatic though sometimes pain and paresthesias may be associated. The lesion may also lead to displacement and compression of surrounding normal nerve tissue.<sup>9</sup> There are only a few isolated case reports of schwannomas arising from mental nerve.<sup>10</sup> Although we did not identify the nerve of origin intra-operatively, the presence of post-operative hypoesthesia over chin and lower lip indicates the origin of tumour from mental nerve.

Imaging techniques such as computed tomography (CT) or magnetic resonance imaging may be important in demarcating tumour margins, lesion composition and whether there is any associated tumour infiltration.<sup>2</sup> However, the definitive diagnosis depends on biopsy and histological study revealing an encapsulated lesion with two characteristic tissue patterns referred to as Antoni A and Antoni B. Immunohistochemically, the lesion is positive for protein S-100 (a specific neural tissue marker), vimentin or other more specific markers such as neuron-specific enolase.<sup>1</sup>

Treatment of choice is complete removal of the encapsulated lesion. Recurrences and development of malignancy are rare events.

## CONCLUSION

High index of suspicion is required and Schwannoma should be considered as a differential diagnosis in oral

cavity benign lesions. The final diagnosis is based on histopathology report and immunohistochemical analysis. The treatment of these tumors is complete resection. The prognosis of such cases is extremely good, without any recurrence.

*Funding: No funding sources*

*Conflict of interest: None declared*

*Ethical approval: Not required*

## REFERENCES

1. Yang SW, Lin CY. Schwannoma of the upper lip: case report and literature review. *Am J Otolaryngol.* 2003;24:351-4.
2. Asaumi I, Konouchi H, Kishi K. Schwannoma of the upper lip: ultrasound, CT, and MRI findings. *J Oral Maxillofac Surg.* 2000;58:1173-5.
3. Baderca F, Cojocaru S, Lazăr E, Lăzureanu C, Faur A, Lighezan R, et al. Schwannoma of the lip: Case report and review of the literature. *Rom J Morphol Embryol.* 2008;49:391-8.
4. Luksic I, Müller D, Virag M, Manojlovic S, Ostovic KT. Schwannoma of the tongue in a child. *J Craniomaxillofac Surg.* 2011;39:441
5. Yilmaz MD, Tokyol C, Dereköy FS, Altuntaş A. Schwannoma of the upper lip: a case report. *Kulak Burun Bogaz İhtisas Dergisi.* 2004;12:42-4.
6. Saydam L, Kizilay A, Kalcioğlu T, Gurer I. Ancient cervical vagal neurilemmoma: a case report. *Am J Otolaryngol.* 2000;21:61-4.
7. Das Gupta TK, Brasfield RD, Strong EW, Hajdu SI. Benign solitary Schwannomas (neurilemmomas). *Cancer.* 1969;24:355-66.
8. Jeffcoat BT, Pitman KT, Brown AS, Baliga M. Schwannoma of the oral tongue. *Laryngoscope.* 2010;120:154.
9. Artzi Z, Taicher S, Nass D. Neurilemmoma of the mental nerve. *J Oral Maxillofac Surg.* 1991;49:196-200
10. Kowatsch E, Feichitingner M, Zeeman W, Krapf E, Karcher H. Extrasosseous schwannoma of the mental nerve clinically simulating intraosseous. *J Oral Pathol Med.* 2006;35:517-9.

**Cite this article as:** Priya R, Virmani N, Dabholkar JP. Schwannoma arising from mental nerve: a rare entity. *Int J Sci Rep* 2016;2(10):265-7.