

Case Report

Simultaneous management of Aphakia and Descemet's membrane detachment after a complicated cataract surgery

Arjun Srirampur*, Swathi Shiva, Gangaprasad Amula, Anupama Kalwad

Department of Ophthalmology, Anand Eye Institute, Hyderabad, Telangana, India

Received: 08 August 2017

Accepted: 24 August 2017

***Correspondence:**

Dr. Arjun Srirampur,

E-mail: sarjuneye@gmail.com

Copyright: © the author(s), publisher and licensee Medip Academy. This is an open-access article distributed under the terms of the Creative Commons Attribution Non-Commercial License, which permits unrestricted non-commercial use, distribution, and reproduction in any medium, provided the original work is properly cited.

ABSTRACT

This report is about an elderly female with surgical aphakia and Descemet's membrane detachment following an eventful cataract surgery undergoing a combined procedure of descemetopexy and intraocular lens placement in same sitting.

Keywords: Descemet's membrane, Descemetopexy, Aphakia

INTRODUCTION

Descemet's membrane detachment (DMD) is a serious complication leading to irreversible corneal decompensation following a wide variety of intraocular surgical procedures. Though improvements in phacoemulsification technology have made it possible to perform cataract surgery through microincision and to achieve better postoperative outcomes, a higher incidence of DMD and endothelial loss has been reported.¹ DMD is still one of the most serious complications of modern cataract surgery. The incidence of clinically significant DMD after phacoemulsification varies between 0.044 and 0.5%.^{2,3} Though rare cases of spontaneous reattachment have been reported, surgical intervention to promote attachment remains the preferred approach. Early treatment is essential to achieve visual rehabilitation and to prevent the wrinkling fibrosis and shrinkage of the Descemet's membrane that can occur over time and result in poor visual outcomes. We report a case of Descemet's membrane detachment after a cataract surgery for which combined procedure of descemetopexy and secondary intraocular lens implantation was done.

CASE REPORT

A 71 year old female was referred to our Cornea clinic with a vision of counting fingers at 2 meters in her right eye. She underwent an eventful cataract surgery elsewhere 1 week ago. Slit lamp examination revealed diffuse corneal edema with striate keratopathy, detached Descemet's membrane from 6' o clock to 12' o clock position involving the visual axis, vitreous strands in anterior chamber, remnants of cortical matter, posterior capsular rent and aphakia (Figure 1). Descemet's membrane detachment was confirmed with anterior segment ocular coherence tomography (AS-OCT) (Figure 2). Left eye was within normal limits. A Secondary IOL implantation and descemetopexy was planned in the right eye. As there was enough anterior capsular support, a +21.00 D single piece PMMA IOL was placed in the sulcus through the previously existing superior scleral incision, after removal of the remaining cortical matter and anterior vitrectomy. During this step care was taken not to touch the detached Descemet's membrane and further worsen it. Descemet's membrane detachment was repaired with injection of perflouropropane (C3F8) gas form a side port incision made opposite to the site of

detachment into the anterior chamber. After waiting for 10 minutes with complete tight gas fill in the anterior chamber, saline was injected to reduce the gas to less than the pupillary diameter. The eye was patched and patient asked to lie down supine position for at least 12 hours. On first post-operative day, vision in right eye was counting fingers at 3 meters, Descemet's membrane was completely attached with gas bubble and IOL was in situ. 2 weeks post operatively vision improved to 6/12, cornea was clear with attached descemet's membrane, gas bubble was still present, IOL was in situ (Figure 3). AS-OCT was done to confirm Descemet's membrane attachment (Figure 4).

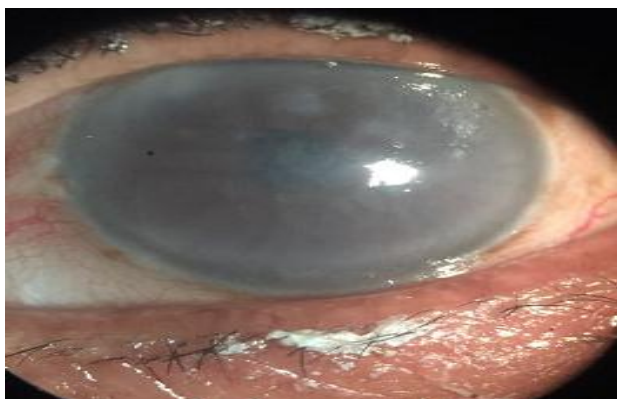

Figure 1: Showing diffuse corneal edema and aphakia.

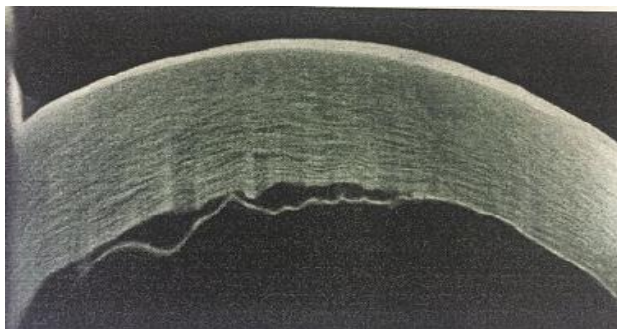


Figure 2: AS-OCT showing Descemet's membrane detachment with overlying corneal edema.

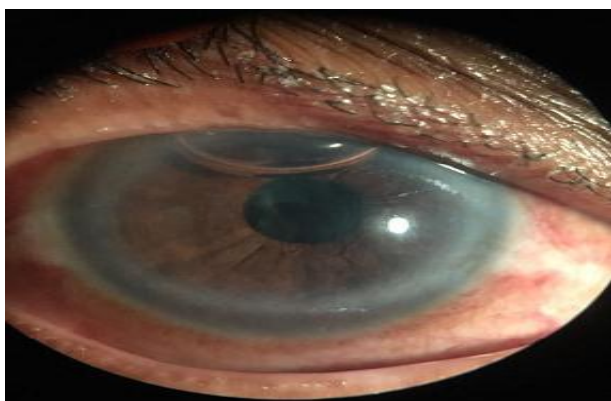


Figure 3: Postoperative picture at 2 weeks showing clear cornea and pseudophakia.

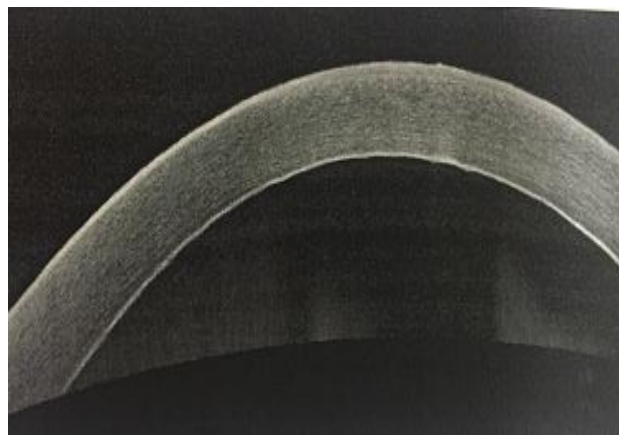


Figure 4: AS-OCT at 2 weeks showing attached Descemet's membrane and clearing of stromal edema.

DISCUSSION

A large Descemet's detachment can lead to epithelial and stromal edema, corneal clouding and compromised vision post operatively. Early surgical intervention is imperative for optimal postoperative visual recovery. The management of Descemet's detachment depends on various factors such as the location and area of the detachment, the degree of antero-posterior separation from the posterior stroma, and the duration of detachment.⁴ Due to the unknown course of the disease, there is no gold standard of treatment for DMD. Surgical repair aims to reapproximate the Descemet's membrane against the stroma using a tamponading agent until it adheres. In descemetopexy, anterior chamber injection of gas to reposition the detached Descemet's membrane, is now well accepted for the management of post-cataract surgery DMD due to its ease of execution and subsequent good outcomes.^{3,4} The success rates with intracameral injections have been reported to be 90–95%.⁵⁻⁷ Tamponading agents successfully used for this purpose include 100% air, sulphur hexafluoride (15–20% SF₆), and perfluoropropane (12–14% C₃F₈). Air is usually preferred for many reasons, including a shorter time of absorption, lower cost, and less risk of endothelial toxicity or pupillary block than with other long-standing gases.⁸ SF₆ and C₃F₈ with their longer resorption time were selected for cases of failing reattachment with air or of detachment for a prolonged period of time. Repeated injections with air or other gases are sometimes required to reposit the DMD. Prolonged Descemet's detachment and corneal edema may sometimes require keratoplasty which can be avoided by timely surgical intervention.⁹ In our case, detachment was 1 week old and was large, so C₃F₈ gas was used and good results was obtained. Our case also shows that descemetopexy can also be combined with intraocular procedures like secondary IOL implantation during the same sitting.

Funding: No funding sources

Conflict of interest: None declared

Ethical approval: Not required

REFERENCES

1. Cheng B, Liu Y, Xie BB, Xi L, Yang Y. Early changes in morphology and intraocular pressure by size of clear corneal incision. *Cornea.* 2011;30:634–40.
2. Ti SE, Chee SP, Tan DT, Yang YN, Shuang SL. Descemet membrane detachment after phacoemulsification surgery: risk factors and success of air bubble tamponade. *Cornea.* 2013;32:454–9.
3. Chow VW, Agarwal T, Vajpayee RB, Jhanji V. Update on diagnosis and management of Descemet's membrane detachment. *Curr Opin Ophthalmol.* 2013;24:356-61.
4. Jain R, Mohan N. Outcomes of repeat descemetopexy in post-cataract surgery descemet membrane detachment. *Am J Ophthalmol.* 2014;157:571.
5. Mahmood MA, Teichmann KD, Tomey KF, al-Rashed D. Detachment of Descemet's membrane. *J Cataract Refract Surg.* 1998;24:827–33.
6. Potter J, Zalatimo N. Descemet's membrane detachment after cataract extraction. *Optometry.* 2005;76:720–4.
7. Jain R, Murthy SI, Basu S, Ali MH, Sangwan VS. Anatomic and visual outcomes of descemetopexy in post-cataract surgery descemet's membrane detachment. *Ophthalmology.* 2013;120:1366–72.
8. Chaurasia S, Ramappa M, Garg P. Outcomes of air descemetopexy for Descemet membrane detachment after cataract surgery. *J Cataract Refract Surg.* 2012;38:1134–9.
9. Mulhern M, Barry P, Condon P. A case of Descemet's membrane detachment during phacoemulsification surgery. *Br J Ophthalmol.* 1996;80(2):185-6.

Cite this article as: Srirampur A, Shiva S, Amula G, Kalwad A. Simultaneous management of Aphakia and Descemet's membrane detachment after a complicated cataract surgery. *Int J Sci Rep* 2017;3(9):256-8.