

## Case Report

# Cu-sil denture: an innovative approach to preserve the few remaining natural teeth: a case report

Divya Goel\*, Dhaniram Talukder, Pankaj Datta, Geeta Paul, Saurabh Singh

Department of Prosthodontics and Crown & Bridge, Inderprastha Dental College and Hospital, Ghaziabad, Uttar Pradesh, India

**Received:** 04 December 2018

**Accepted:** 21 December 2018

### \*Correspondence:

Dr. Divya Goel,

E-mail: [dhaniramtlkdr@gmail.com](mailto:dhaniramtlkdr@gmail.com)

**Copyright:** © the author(s), publisher and licensee Medip Academy. This is an open-access article distributed under the terms of the Creative Commons Attribution Non-Commercial License, which permits unrestricted non-commercial use, distribution, and reproduction in any medium, provided the original work is properly cited.

### ABSTRACT

According to De Van, the preservation of what remains is of utmost importance rather than the meticulous replacement of what has been lost. Need based use of unconventional approach is a growing demand in prosthodontics in India. The increasing demands of the patients have led to innovative techniques for fabricating complete dentures. Conventional techniques may provide satisfactory results in most patients but may not be suitable in all cases. Cu-sil denture is one of the transitional dentures which is easy to fabricate, saves time as well as reduces the cost of treatment. These dentures provide a psychological boost to the patients and serve as a viable alternative. They not only promote the alveolar ridge integrity but also help in retaining the proprioceptive ability of the periodontium. This paper presents a case of fabrication of Cu-sil denture in a patient with two teeth remaining in the maxillary arch.

**Keywords:** Cu-sil denture, Transitional denture, Alveolar ridge

### INTRODUCTION

Successful treatment is dependent upon the preservation of residual alveolar ridge. The preservation of remaining natural teeth helps in preserving the alveolar ridge integrity and proprioceptive ability of the periodontium.<sup>1</sup>

Earlier it was considered that extraction of all remaining natural teeth followed by complete denture replacement is inexpensive and permanent solution for management of missing teeth which led to a major oral morphological problem like advanced residual ridge resorption (RRR).<sup>2</sup>

Nowadays, several treatment options are available for patients having very few remaining natural teeth which includes over dentures, transitional dentures, immediate dentures following complete extractions of remaining teeth or implant supported prosthesis.

Cu-sil denture in one of the transitional dentures which serve as a treatment option for preservation of few remaining natural teeth and for the patients who do not want to go for extraction of remaining natural teeth as it has a mutilating effect on their psychology.<sup>3</sup>

Cu-sil denture is a type of complete denture with holes allowing the remaining natural teeth to emerge through the denture. The holes are surrounded by the gasket of silicone rubber which clasps the neck of natural teeth, thus allowing a natural suction to form under the denture.<sup>4</sup>

The fabrication of Cu-sil denture does not require any tooth preparation or any extra laboratory procedures. If in future the remaining teeth are lost, then existing denture can be modified to occupy its missing place.<sup>5</sup>

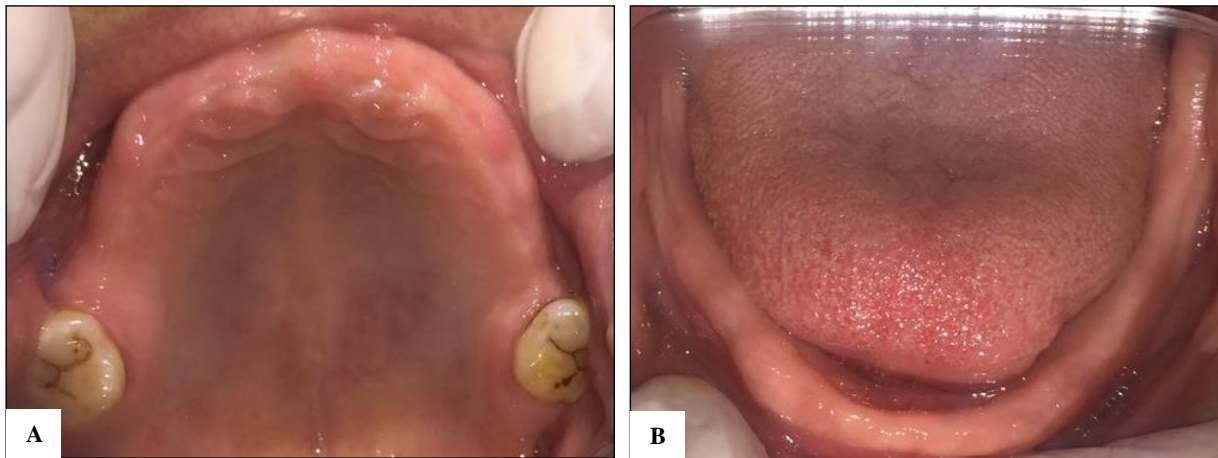
Indications of Cu-sil denture include patients who do not want to lose their remaining teeth but cannot be adequately treated with fixed or other removable partial denture, patients with few remaining teeth whose mucosa, supporting bone, or general health, suggests a poor prognosis for complete dentures and patients with natural maxillary teeth oppose a mandibular complete denture.<sup>6</sup>

Contraindications include patients with too many remaining teeth, patients with poor oral hygiene and poor plaque control and in case of those teeth which are exhibiting unfavorable undercuts hindering with the denture fabrication and placement.<sup>7</sup>

This case report presents an alternative approach, Cu-sil denture, which helps in preservation of few remaining natural teeth by resting on the soft tissues and offering a comfortable fit over the existing, healthy teeth structures.

### CASE REPORT

A 56-year-old female patient reported to Department of Prosthodontics and Crown & Bridge, Inderprastha Dental College and Hospital, Ghaziabad, India with the chief complaint of difficulty in eating and speaking due to teeth loss. The patient presented with only two posterior teeth remaining (17 and 27) and all other teeth were extracted 8 months ago. On clinical examination, it was revealed that 17 and 27 were periodontally sound and mandibular arch was completely edentulous (Figure 1).



**Figure 1: Preoperative maxillary and mandibular arch.**

Treatment plan was explained to the patient with over denture in the maxillary arch and conventional complete denture in mandibular arch. Therefore, root canal treatment in the remaining two posterior teeth was advised but she was not willing for any other procedure other than replacement of missing teeth. So, the treatment plan was modified to transitional denture (Cu-sil denture) from maxillary overdenture.

### TECHNIQUE

Primary impression of maxillary arch was made with irreversible hydrocolloid impression material (Alginate) and mandibular edentulous arch was made with modeling plastic impression compound in a metal stock tray.

The cast was poured using dental plaster for mandibular arch and dental stone for maxillary arch. A custom tray was fabricated on the maxillary cast with double spacer on the remaining teeth to prevent the action of undue forces on the teeth. Border molding of the maxillary arch was performed with green stick impression compound and secondary impression was made with addition silicone light body impression material (Figure 2). For the mandibular arch, conventional steps were performed.

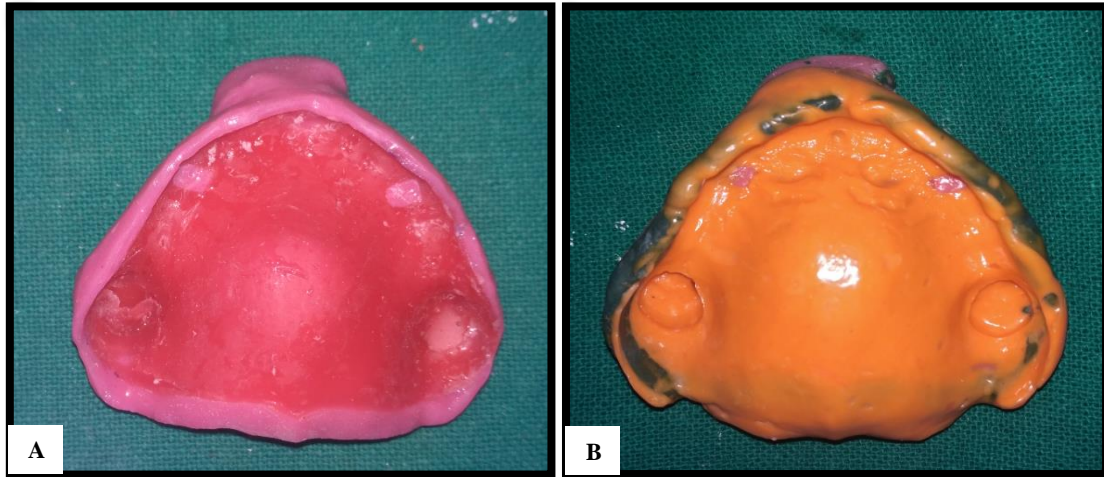
The secondary impressions were poured with dental stone. Acrylic denture bases were made for the master casts and occlusal rims were fabricated (Figure 3).

After the recording of maxillo-mandibular relationship, both casts were mounted on articulator. Artificial teeth arrangement was done with conventional manner and try in procedure was performed. The patient's phonetics and esthetics were evaluated (Figure 4).

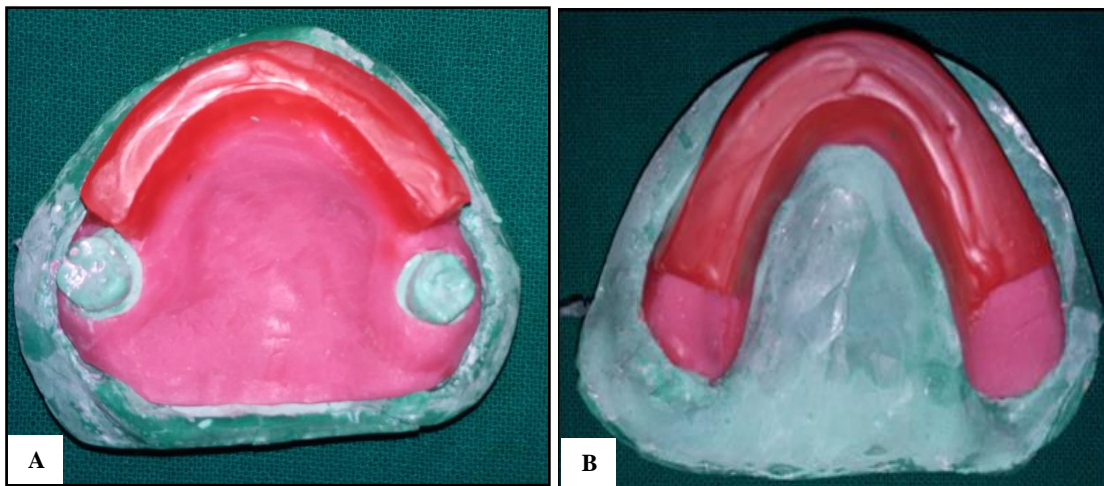
Before dewaxing mechanical undercuts of the remaining natural teeth were examined with the help of a surveyor and blocked out using dental plaster (Figure 5).

Acrylization of the maxillary and mandibular denture was done in the conventional manner (Figure 6).

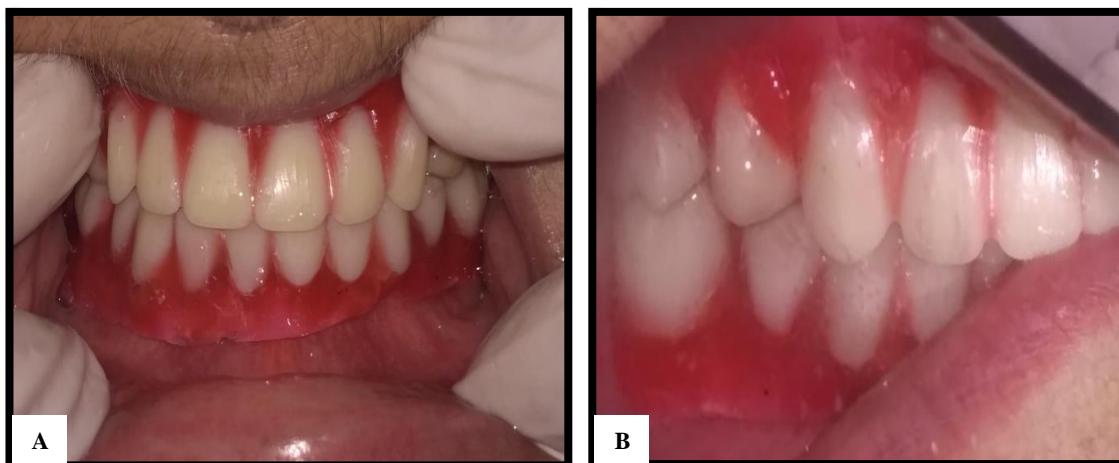
After fabrication, maxillary Cu-sil denture was finished and polished. In the 17 and 27 regions, relief space was created around the teeth in which acrylic-based soft liners were placed. After relining, denture was inserted in the patient's mouth and held in position till the final setting of the material. Denture was removed and excess was trimmed (Figure 7).



**Figure 2: Border molding was performed with green stick impression material and secondary impression was made with addition silicone light body impression material.**

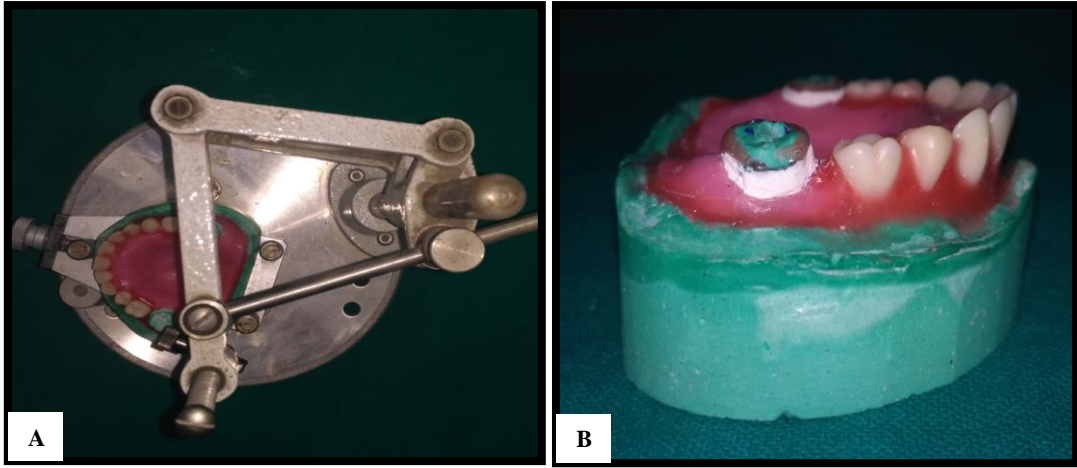


**Figure 3: Acrylic denture base and occlusal rims were fabricated.**

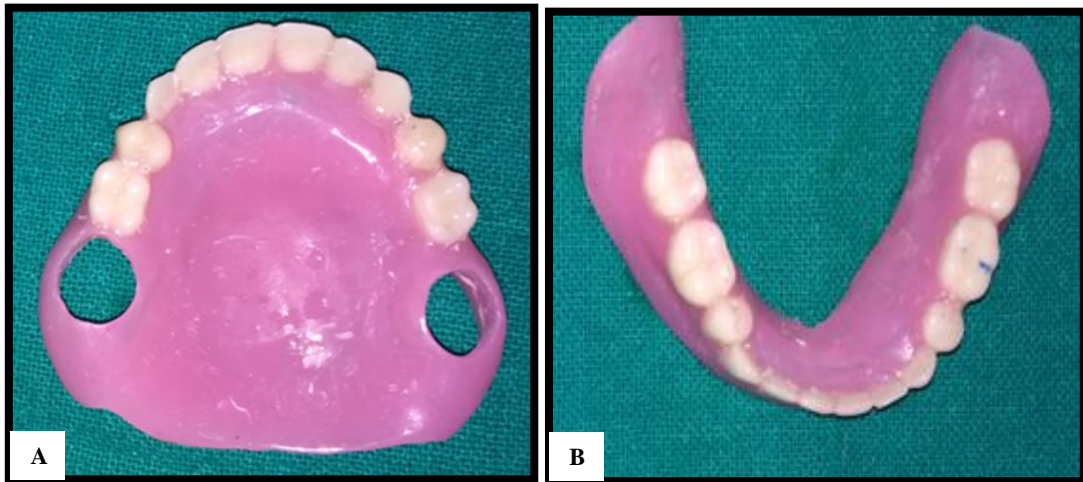


**Figure 4: Try in procedure was performed.**

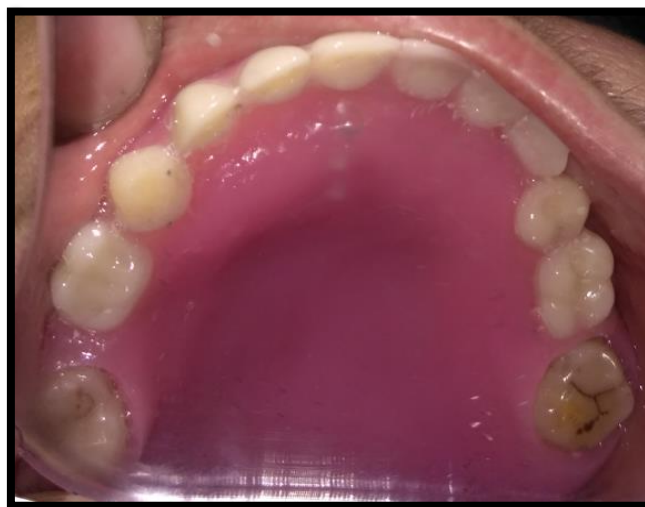



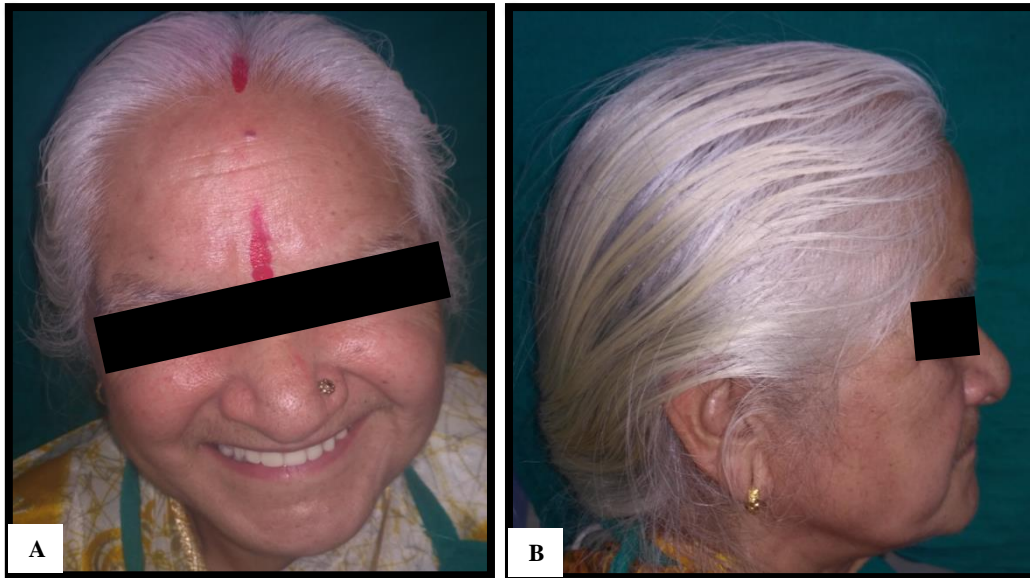**Figure 5: Mechanical undercut of the remaining natural teeth was examined with the help of a surveyor and blocked out using dental plaster.**



**Figure 6: Final maxillary Cu-sil denture and mandibular complete denture.**



**Figure 7: Relining of the relief space with acrylic based soft liner material.**



**Figure 8: Postoperative extra oral view of maxillary Cu-sil denture with mandibular complete denture.**

Insertion of the final maxillary Cu-sil denture and mandibular complete denture was performed and the denture was examined for retention, stability, support, phonetics and esthetics (Figure 8). Post-insertion instructions similar to a conventional denture were given to the patient.

### DISCUSSION

Preservation of the remaining natural teeth helps in preserving the PDL which prevents the residual ridge resorption. Preserving the remaining natural teeth also helps in regulating the natural jaw reflexes and provides a psychological benefit to the patients.<sup>8</sup>

Due to its viscoelastic properties, soft liners are the best choice as a relining material as they provide cushion like effect which can distribute forces more evenly by absorbing energy.<sup>9</sup>

Some critical clinical points that a practitioner usually finds with this transitional denture include patients with too many teeth exhibiting unfavorable undercuts which would hinder with its fabrication and placement of the denture and creating too many holes to accommodate natural teeth would compromise the strength of the final denture.<sup>10</sup>

Frequent correction of soft liner material is necessary in Cu-sil denture. Rate of plaque accumulation is increased as the entire gingival margin of remaining teeth is covered.<sup>11</sup> Cu-sil denture should be avoided in patients with parafunctional habit like bruxism, severe undercut areas and patient with high smile line.<sup>12</sup>

There are possible chances of fungal growth on the soft liner material. Special care should be taken regarding

maintenance of excellent oral and denture hygiene. The use of denture cleansers with antimicrobial agents is recommended.

### CONCLUSION

Transitional dentures like Cu-sil denture serve as an alternative treatment for patients with very few remaining teeth. It improves the retention of the denture with maintaining the existing vertical dimension and without requirement of any attachment devices. Cu-sil denture helps in preservation of teeth, thereby preserving alveolar ridge integrity and proprioceptive ability of periodontium which has positive psychological effect on patient. Patients who do not want to undergo the treatment option for overdenture or extraction of remaining natural teeth, transitional denture like Cu-sil denture is one of the best treatment options for preservation of remaining natural teeth.

*Funding: No funding sources*

*Conflict of interest: None declared*

*Ethical approval: Not required*

### REFERENCES

1. Guyer SE. Selectively retained vital roots for partial support of overdenture. *J Prosthet Dent.* 1975;33(3):258-63.
2. Cu-sil Denture: A Novel conservative approach. *UJMSD.* 2007;1(02):56-8.
3. Zarb GA, Bolender CL, Hickey JC, Unnar EG, Carlsson. *Boucher's Prosthodontic treatment for edentulous patients.* 10th ed. Mosby; 71-99.
4. Khandelwal M, Punia V. Saving one is better than none: Technique for cu-sil like denture – A case report. 2011;3(1):41-5.

5. Schwartz S, Morrow RM. Overdentures-Principles and Procedures. *Dental Clin North America.* 1996;40(1):169-94.
6. Jain J, Prabhu C, Zahrane M, Esawy M, Ajagannavar S, Pal K. Cu-sil dentures—a novel approach to conserve few remaining teeth. *JIOH.* 2015;7(8):138-40.
7. Jain A. Cu sil denture for patients with few remaining teeth-a case report. *IJRID.* 2014;4(4):98-103.
8. DeVan MM. Transition from natural to artificial teeth. *J Prosthet Dent.* 1961;11:677-88.
9. Braden M, Wright P, Parker S. Soft lining materials—a review. *Euro J Prosthodont Restor Dent.* 1995;3:163–74.
10. Gagandeep K, Sangeetha G, Deepika S. Cusil denture: A novel conservative approach-A case report. *Unique J Med Dent Sci.* 2013;1:56-8.
11. Walter J. A study of partial denture designs produced by an alumni group of dentists in health service practice. *Eur J Prosthodont Restor Dent.* 1995;3:135-9.
12. Smith S, Heffler S, Freeland M. The next decade of health spending: A new outlook. The National Health Expenditures Projection Team. *Health Aff (Millwood).* 1999;18:86-95.

**Cite this article as:** Goel D, Talukder D, Datta P, Paul G, Singh S. Cu-sil denture: an innovative approach to preserve the few remaining natural teeth: a case report. *Int J Sci Rep* 2019;5(1):29-34.