

## Case Report

# Accidental aspiration of endodontic file: a dreaded but a preventable complication

Pranav Ish<sup>1</sup>, Vidushi Rathi<sup>1</sup>, Imran Khan<sup>2</sup>, Khushboo Khan<sup>3</sup>, Shubham Datta<sup>2\*</sup>

<sup>1</sup>Department of Pulmonary, Critical Care and Sleep Medicine, VMMC and Safdarjung Hospital, New Delhi, India

<sup>2</sup>Department of Oral and Maxillofacial Surgery, Faculty of Dentistry, Jamia Milia Islamia, New Delhi, India

<sup>3</sup>Private Practitioner, K.G. Medident, A-241, Govindpuram, Ghaziabad, Uttar Pradesh, India

**Received:** 31 January 2020

**Revised:** 20 March 2020

**Accepted:** 31 March 2020

**\*Correspondence:**

Dr. Shubham Datta,

E-mail: [dattashubham1998@gmail.com](mailto:dattashubham1998@gmail.com)

**Copyright:** © the author(s), publisher and licensee Medip Academy. This is an open-access article distributed under the terms of the Creative Commons Attribution Non-Commercial License, which permits unrestricted non-commercial use, distribution, and reproduction in any medium, provided the original work is properly cited.

### ABSTRACT

Accidental ingestion of dental objects has been reported previously in literature. Accidental aspiration of a dental object is however uncommon. The affected patient may exhibit varying range of symptoms depending on location, type, shape and size of the foreign body swallowed/aspirated. We report a case about successful retrieval of an aspirated endodontic file with special focus on risk factors, prevention and management of these iatrogenic complications.

**Keywords:** Aspiration, Endodontic file, Haemoptysis

### INTRODUCTION

Accidental aspiration or ingestion of a dental object is an unfortunate and a dreaded complication that can occur during any dental procedure. In dental operator, the ingested foreign body may include teeth, restorations, restorative materials, instruments, rubber dam clamps, gauze packs, and so forth.<sup>1</sup>

The principle of nonmaleficence would dictate that safety (that is, accident prevention) should always come to mind when the patient is positioned for any dental treatment. Schneider commented that some dental patients might be predisposed to foreign body ingestion/aspiration; these patients included the very young, the elderly, and those with muscular dystrophy, multiple sclerosis, epilepsy, or other medical conditions that might compromise the gag reflex.<sup>2</sup> By contrast, Tiwana et al found a relatively infrequent occurrence of adverse outcomes in special care, physically handicapped, and pediatric populations, which she

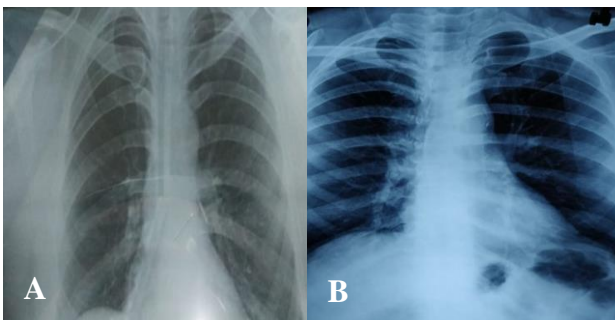
attributed to those patients receiving fewer cast restorations and implants.<sup>3</sup> In addition, all of the adverse events she discovered occurred during treatment for which local anesthetic was not given; this finding contradicts the rationale that decreased oral sensory input increases the likelihood of ingestion/aspiration.<sup>4</sup> The only conclusion that can be made at this point is that any patient could swallow or aspirate an unsecured dental item during treatment.

Grossman reported that most (87%) of the foreign bodies (FB) enter the gastrointestinal tract and the remaining 13% enter the respiratory tract.<sup>5</sup> Aspiration of any foreign body can be a medical emergency requiring urgent intervention. A wide range of ingested/aspirated dental objects have been reported in the literature varying from an entire Tooth to tooth roots, dental restorations, prosthetic crowns, endodontic files, burs, dental implant components. The symptoms from aspiration may vary from patient to patient depending upon the type, shape, size and location of the aspirated dental object. We here

report a case of successful retrieval of an aspirated endodontic file from an otherwise healthy individual who reported to a pulmonologist with chief complaint of haemoptysis. The patient was unaware of the incident. This case also emphasises on the various risk factors that can possibly be identified preoperatively along with a brief overview on prevention and management of these complications.

### CASE REPORT

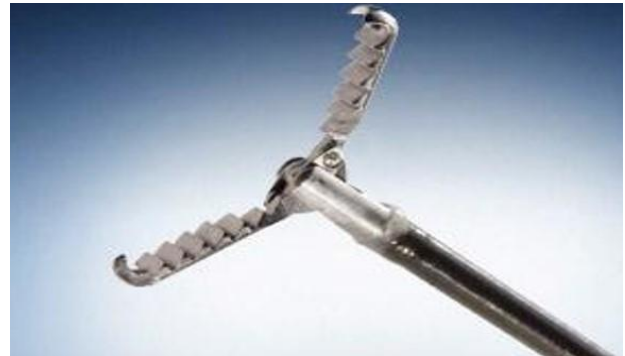A 35 years old man presented to pulmonary outpatient department with complaints of cough with haemoptysis in the last 3 days. Cough was episodic with no postural or diurnal variations. Haemoptysis was 2 to 3 times per day, around 10 ml in each episode and only for 3 days duration. There was no history of bleeding from any other site, drug intake or syncope after haemoptysis. There was no history of fever, breathlessness, wheeze or stridor. The patient also complained of diffuse chest pain, not relieved by oral antacids and analgesics. The patient had stable vitals, pulse – 80/minute, blood pressure - 118/78 mm Hg, and saturation of 98% on room air. On respiratory examination, there were bilateral vesicular breath sounds with equal intensity with no added sounds. Cardiovascular auscultation was normal. A complete blood count, kidney and liver function test and prothrombin time were normal. The patient was planned for radiological investigations and sputum analysis. The chest X-ray (Figure 1A) however, revealed a long thin radio-opaque foreign body lodged in the left main bronchus near the hilum. On retrospective detailed interrogation, the patient revealed a history of undergoing a root canal treatment five days prior to presentation in a suburban area for a tooth cavity in the left mandibular 2<sup>nd</sup> premolar. The procedure was not associated with or followed by any pain.



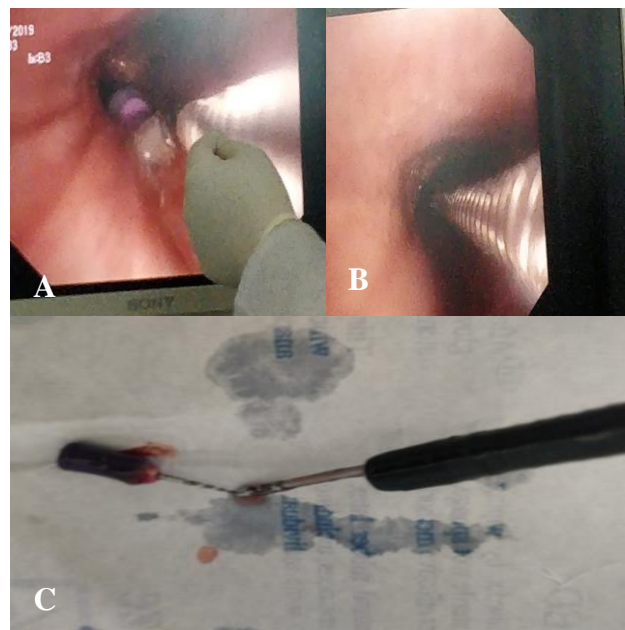
**Figure 1: (A) Pre-operative X-ray showing endodontic file, (B) post-operative chest X-ray.**

On discussion with dental colleagues, it was believed to be an endodontic cleaning and shaping file. The patient was prepared and taken up for bronchoscopy on the same day of presentation. Under sedation, analgesia and local anesthesia, the flexible fibre-optic bronchoscope was introduced. The file was easily identified in the left main bronchus with the pointed end lodged into the lateral wall of the bronchus. A rat tooth alligator jaw grasping forceps

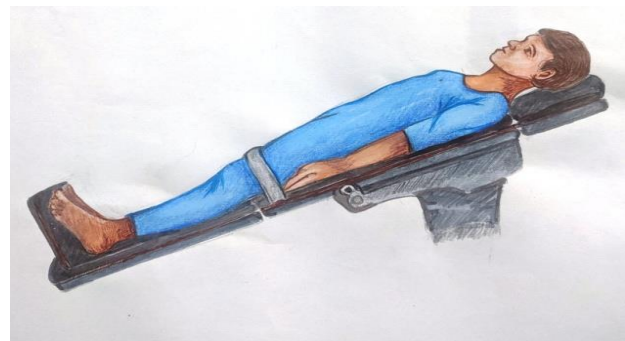
(Figure 2) was used to hold the file and pull the entire file into the lumen. As the end of the file is pointed, the file was held by the forceps and removed in total with the entire assembly of the bronchoscope (Figure 3A-C). The post procedure X-ray revealed no complication and clearing of the foreign body shadow (Figure 1B). The patient was discharged after 12 hours observation on next morning with no medications.



**Figure 2: Rat tooth alligator jaw grasping forceps.**



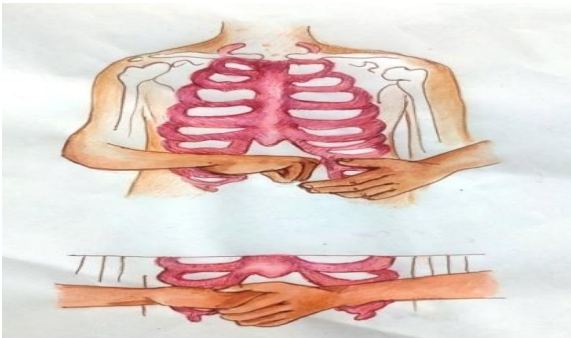
**Figure 3 (A-C): Retrieved endodontic file.**



**Figure 4: Patient in recline position.**



**Figure 5: Heimlich maneuver.**



**Figure 6: Abdominal or chest thrusts.**

## DISCUSSION

Dental items have been determined as the second most commonly ingested/aspirated foreign objects in adults.<sup>6-8</sup> A study reported that less than 10 percent are aspirated and most are ingested.<sup>9</sup> In the domain of endodontic instruments, Susini et al found that the incidence of aspiration was 0.001 per 100,000 root canal treatments and the incidence of ingestion was 0.12 per 100,000 root canal treatments. The aspirated endodontic instruments and dental items required statistically more frequent hospitalization than the ingested items ( $p < 0.0001$ ).<sup>10</sup>

During any intervention related to the oral cavity, it is very important to identify the potential risk factors for accidental aspiration/ingestion of foreign bodies to avoid the potential life-threatening emergencies. Predisposing factors involved are reduced laryngeal closure, elderly patients, patients sedated by intravenous drugs, inebriated, mentally handicapped, or traumatized patients with altered states of consciousness are usually more susceptible because of the decreased gag reflex, swallowing incoordination, or other impaired protective airway mechanisms. Besides neurologic conditions, such as stroke, dementia, cerebral palsy, brain tumors/injuries, Parkinson's disease, amyotrophic lateral sclerosis usually have higher risk due to functional impairment of swallowing mechanism.<sup>2</sup> Some other risk factors that might inadvertently lead to ingestion or aspiration are the numbing effect of anesthetic agents and loss of gag reflex mechanism, excessive or unexpected patient movements

during treatment, inadequate lighting, ineffective assistance, limited mouth opening, inadequate suction of saliva and unexpected breakage or detachment of poor quality instruments.<sup>11</sup> Inappropriate size of gloves may also lead to faulty manoeuvre of dental instruments leading to accidental aspiration or ingestion especially of endodontic files and prosthodontic crowns.

Aspiration can occur at any level of airway but the right bronchus is most common site in adults because the left main bronchus is connected with the trachea at a sharper angle as compared with the right main bronchus. In adults only 5-11% remain in the trachea where as in children FBs may be found on both sides with equal propensity.<sup>12</sup> However, the site of impaction of FBs may ultimately depend on the position of the patient at the time of inhalation. The general trend in dentistry is to treat patients in a supine position to improve visibility, accessibility to the oral cavity as well as the ergonomic comfort for operators. Although the supine position seems more susceptible to accidental aspiration/ingestion of foreign bodies.<sup>21</sup>

In a review done by Ahmed et al a preferential lodgement of FBs was found in the left bronchus than the right with 22.9% and 17.1%, respectively. The right main bronchus is commoner in the erect position and right lateral position while FBs which are small enough preferentially lodge in the left main bronchus in the left lateral position<sup>13</sup>. In our case the endodontic file being small, patient position while treatment might have predisposed to the aspiration in left bronchus. The symptoms vary with the level of obstruction. The most common symptoms of laryngotracheal obstruction are dyspnoea, cough, and stridor. Laryngeal choking of the airway by foreign objects results in respiratory difficulty with or without cyanosis along with hands clutched to the throat, depending on whether the choking is partial or complete. Bronchial foreign bodies are associated with cough, decreased air entry, dyspnea, and wheeze. Some inadvertently aspirated small foreign objects that might pass through the vocal cords without obstructing the upper airway remain asymptomatic for several months leading to late complications such as vocal cord paralysis, post obstructive pneumonia, atelectasis, bronchiectasis, pneumothorax, haemorrhage or lung abscess and even death.<sup>11</sup> Haemoptysis is also of common clinical occurrence. Besides common causes like infection, lung neoplasms, bronchiectasis, a wide variety of other causes are seen and idiopathic in up to 30% cases.<sup>14</sup> Various types of foreign bodies have been reported in the literature, like eatables, pieces of plastic, metal, teeth, stone, bead, balloon needle, thread, etc., as causes of massive haemoptysis.<sup>15-17</sup>

Though mostly ingested foreign bodies pass through the GI tract uneventfully. They might lead to dysphagia, odynophagia, coughing, gagging, drooling of saliva, chest pain, muscle incoordination, incessant twitching, nausea, hematemesis, and regurgitation.<sup>11</sup>



## Management

When any accidental aspiration or ingestion occurs, clinician must first reassure the patient and must be competent enough to differentiate between the two. Thorough evaluation must be done to facilitate the timely course of action. When the object seems to be aspirated, patient should be positioned in a reclined phase (Figure 4), and encouraged to cough forcibly to ensure a clear airway. If airway is getting compromised with symptoms such as inspiratory stridor, choking, and forced breathing noninvasive procedures for instance Heimlich maneuver as depicted in the (Figure 5), abdominal or chest thrusts (Figure 6) should be carried out to alleviate the obstruction.

When the object is not retrieved by above mentioned maneuvers, then comprehensive diagnostic tests (chest and abdomen radiographs) must be carried out to ensure its location. Furthermore, CT scan and bronchoscopy can also aid in localizing the object in respiratory tract.

Once the location is confirmed bronchoscopy remains the standard in retrieving of the lost object. Hou reported that bronchoscopy has been reported 99% effective on retrieve the aspirated foreign objects.<sup>18</sup> In our case we opted for flexible fiberoptic bronchoscopy as it is relatively safe, more efficient and easier to perform with as high success rate (>90%) as rigid bronchoscopy. Moreover, it can be performed under local anaesthesia whereas rigid bronchoscopy requires general anaesthesia. The advantages of initial flexible bronchoscopy include cost effectiveness and the ability to be performed as an outpatient procedure. Rigid bronchoscopy is pursued in cases where flexible bronchoscopy is unsuccessful or inadequate for safe extraction and simultaneous airway management. In addition, if foreign bodies are impacted by significant granulation tissue or are difficult to grasp with flexible forceps due to size or shape, rigid bronchoscopy should be used for extraction. Endobronchial ablation, cryotherapy, or airway dilation techniques may be necessary in cases where foreign body retention has caused significant granulation tissue or airway stenosis.<sup>19</sup>

If the foreign body has entered the GI tract, the most common sites of impaction being areas of physiologic angulation or pathologic narrowing, such as the pharynx, upper esophageal sphincter, middle third of the esophagus, lower esophageal sphincter, pylorus, duodenojejunal flexure, ileocecal junction, appendix, rectosigmoid junction, anus, or patients with previous GI surgery or congenital gut malformations. The literature highlights that although 90% of ingested foreign objects could pass through the gastrointestinal tract uneventfully, there are roughly 10% which require endoscopic removal, while still 1% will ever require operation. Flexible endoscopy is the procedure of choice to retrieve such objects in the GI tract. The most common site of obstruction is upper esophagus which should be dealt

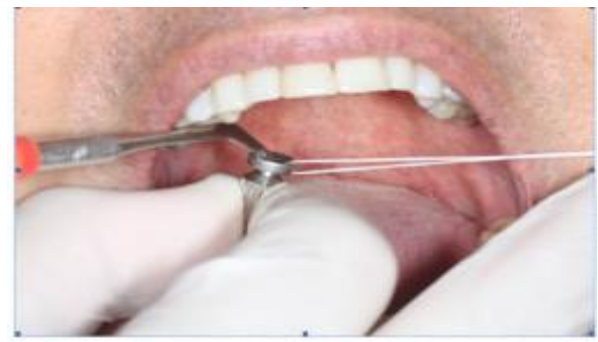with oesophagoscopy as it can lead to risks of aspiration and esophageal perforation with secondary mediastinitis. It has been reported by Govilla et al that endodontic instruments entering the GI tract pass out spontaneously in the feces in 4 days to 2 weeks. In case of sharp object regular assessment and serial radiographic monitoring of the progress of such an object is advised to alleviate any perforation especially in proximal duodenum. In the meantime, the patients should observe their stools to confirm the passage of the foreign body. Use of a high-coarse fibre diet may be beneficial for the same.<sup>11</sup>

## Preventive measures

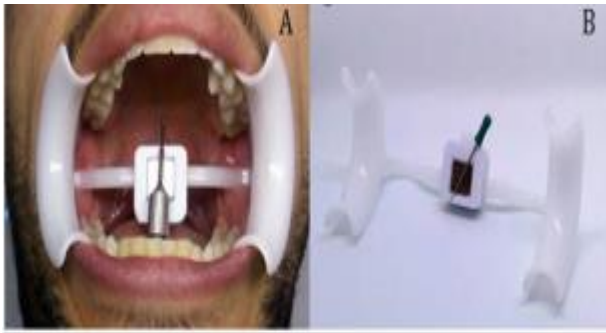Hou et al did a review on thorough documentation of the accidental aspiration and ingestion of foreign objects during dental procedure in 617 cases and concluded that each accident should have thorough documentation so as to provide enough information for the treatment and prevention. Although several strategies have been employed in dentistry to avoid aspiration or ingestion of foreign objects, prevention is considered as the best method for managing such episodes.<sup>18</sup>

The Mallampati score can be used to measure risk factor of the patient. It is based by asking the patient (in a sitting posture) to open his/her mouth and protrude the tongue as much as possible. The anatomy of the oral cavity is visualized; specifically, whether the base of the uvula, faucial pillar and soft palate are visible. Depending on whether the tongue is maximally protruded and/or the patient asked to phonate, the scoring may vary. Mallampati Scoring: Class I: Soft palate, uvula, fauces, pillars visible. Class II: soft palate, uvula, fauces visible. Class III: soft palate, base of uvula visible. Class IV: only hard palate visible.<sup>22</sup>

In many dental procedures (e.g., implant and prostheses), usually application of rubber dam is not followed, which causes frequent ingestion of foreign bodies without the knowledge of the patient or the operator and even without any clinical signs. So, to prevent these conditions, it is always better to count the instruments before starting procedures and recounting them at the end of them.



**Figure 7: Dental floss preventing accidental ingestion during dental procedure.<sup>24</sup>**



**Figure 8: Dental lip retractor, with a magnet (A) it is shown an implant hex drive hold by the magnet on the lip retractor, (B) is an endodontic file hold by the magnet also.<sup>24</sup>**

The placement of a rubber dam is considered the standard of care. with the advent of new endodontic devices, new safety challenges have arisen and must be considered in addition to the placement of a rubberdam.<sup>20</sup> The cases which does not support rubber dam, other options like gauze throat screens, high vacuum suction, customized impression trays, floss ligatures for minor items, use of more upright position are the key to minimize risk of ingestion or aspiration.

It is reported by Ratnaditya et al, 2014 dental floss which is used to stabilize the hex drive is tied to a gold ring and the ring is put in position on the operator's finger ring to overcome sudden aspiration of fallen instrument (Figure 7).<sup>25</sup> The pivotal role of gloves: Appropriate size of gloves is recommended as oversized gloves might lead to faulty manouvre of small sized instruments for instance endodontic instruments, prosthodontic and orthodontic components like brackets etc., leading to accidental aspiration.

Another possible step is the Lip retractor, which is associated with two neodymium's magnets (vertical draw force 1.4 kg, magnetic grille N42, magnetic field in the distance of 0 mm 2230 gauss). This device can be used to prevent foreign bodies from being ingested, namely those which are attached by magnets. Its use is indicated for many dental procedures, maintaining mouth tissues retracted, allowing more visibility for the practitioner and preventing accidental ingestion. During the procedure, if there is any accidental fall of instruments, the lip retractor with the magnet will attract and hold the instrumental before entering the esophagus or trachea or even before touching the soft palate that triggers the gag reflex (Figure 8).<sup>24</sup>

## CONCLUSION

Dentists must take proper precautions to minimize any risk of such unforeseen complications of aspiration or ingestion especially in patients that are more prone to such risks. Proper assessment of the patients and the armamentarium used for treatment should be done.

Preventive measures such as rubber dam, throat screen etc., should be made mandatory in day to day practice which we often neglect. Proper assessment and monitoring of the patient must be done in cases of aspiration or ingestion.

## ACKNOWLEDGEMENTS

We would like to acknowledge Ms. Shabnam from Faculty of Fine Arts, Jamia Millia Islamia, New Delhi, India, for her artistic contribution of drawings to our article.

*Funding: No funding sources*

*Conflict of interest: None declared*

*Ethical approval: Not required*

## REFERENCES

- Holan G, Ram D. Aspiration of an avulsed primary incisor. A case reports. Int J Paediatr Dent. 2000;10:150-2.
- Tiwana KK, Morton T, Tiwana PS. Aspiration and ingestion in dental practice: a 10-year institutional review. J Am Dent Assoc. 2004;135:1287-91.
- Hill EE, Rubel B. A practical review of prevention and management of ingested/aspirated dental items. Gen Dent. 2008;56:691-4.
- Schneider PE. Foreign body aspiration and ingestion during dental treatment. Compend Contin Educ Dent. 1982;3(3):173-6.
- Tiwana KK, Morton T, Tiwana PS. Aspiration and ingestion in dental practice: A 10-year institutional review. J Am Dent Assoc. 2004;135(9):1287-91.
- Wilcox CW, Wilwerding TM. Aid for preventing aspiration/ingestion of single crowns. J Prosthet Dent. 1999;81(3):370-1.
- Grossman LI. Prevention in endodontic practice. J Am Dent Assoc. 1971;82:395-6.
- Fields RT, Schow SR. Aspiration and ingestion of foreign bodies in oral and maxillofacial surgery: A review of the literature and report of five cases. J Oral Maxillofac Surg. 1998;56:1091-8.
- Limper AH, Prakash UB. Tracheobronchial foreign bodies in adults. Ann Intern Med. 1990;112:604-9.
- Tiwana KK, Morton T, Tiwana PS. Aspiration and ingestion in dental practice: A 10-year institutional review. J Am Dent Assoc. 2004;135:1287-91.
- Webb WA, Daniel ML, Jones L. Foreign bodies of the upper gastrointestinal tract: Current management. South Med J. 1984;77:1083-6.
- Susini G, Pommel L, Camps J. Accidental ingestion and aspiration of root canal instruments and other dental foreign bodies in a French population. Int Endod J. 2007;40:585-9.
- Yadav RK, Yadav HK, Chandra A, Yadav S, Verma P, Shakya VK. Accidental aspiration/ingestion of foreign bodies in dentistry: A clinical and legal perspective. Natl J Maxillofac Surg. 2015;6:144-51.

14. Hewlett JC, Rickman OB, Lentz RJ, Prakash UB, Maldonado F. Foreign Body Aspiration In Adult Airways: Therapeutic Approach. *J Thorac Dis.* 2017;9(9):3398-409.
15. Ahmed AO, Shuiabu IY. Inhaled foreign bodies in a paediatric population at AKTH Kano-Nigeria. *Niger Med J.* 2014;55(1):77-82.
16. Weinberger SE, Barunwald E. Cough and hemoptysis. In: Braunwald E, Fauci AS, Kasper DL, Hauser SL, Longo DL, Jameson JL, editors. *Harrison's Principles of Internal Medicine*; 15th edition. Philadelphia: McGraw-Hill; 2001:203-206.
17. Debeljak A, Gorli J, Music E, Kecel JT. Bronchoscopic removal of foreign bodies in adult: experience with 62 patients from 1974-1988. *Eur Respir J.* 1999;14:792-5.
18. Baharloo F, Veyckemans F, Francis C, Bieltlot MP, Rodenstein DO. Tracheobronchial foreign bodies: presentation and management in children and adult. *Chest.* 1999;115:1357-62.
19. Cakir E, Torun E, Uyan ZS, Akca O, Soysal O. An unusual case of foreign body aspiration mimicking cavitary tuberculosis in adolescent patient: thread aspiration. *Italian J Pediatr.* 2012;38:17.
20. Hou R, Zhou H, Hu K, Ding Y, Yang X, Xu G, et al. Thorough documentation of the accidental aspiration and ingestion of foreign objects during dental procedure is necessary: review and analysis of 617 cases. *Head Face Med.* 2016;12:23.
21. Fang YF, Hsieh MH, Chung FT. Flexible bronchoscopy with multiple modalities for foreign body removal in adults. *PLoS ONE.* 2015;10(3):8993
22. Ingle JI, Bakland LK, Baumgartner JC, editors. *Endodontic Mishaps.* Ingle's Endodontics. 5th ed. Hamilton: BC Decker; 2008:792.
23. Cameron SM, Whitlock WL, Tabor MS. Foreign body aspiration in dentistry: A review. *J Am Dent Assoc.* 1996;127:1224-9.
24. Prevention from swallowing or aspiration in dentistry for elderly patients, Gustavo Ismael, Lanamar de Alameida, Tania e Silva Pulicano Lacerda.
25. Lyons MFII, Tsuchida AM. Foreign bodies of the gastrointestinal tract. *Med Clin North Am.* 1993;77(5):1101-14.

**Cite this article as:** Ish P, Rathi V, Khan I, Khan K, Datta S. Accidental aspiration of endodontic file: a dreaded but a preventable complication. *Int J Sci Rep* 2020;6(5):184-9.