

## Case Report

# Hepatocellular carcinoma with extrahepatic adrenal metastasis: an atypical case report

Diptajit Paul, Baljit Singh\*, Rakesh Dhankhar, Vivek Kaushal

Department of Radiation Oncology, Pt. B. D. Sharma PGIMS, Rohtak, Haryana, India

**Received:** 11 May 2021

**Accepted:** 02 June 2021

**\*Correspondence:**

Dr. Baljit Singh,

E-mail: docbaljeet13@gmail.com

**Copyright:** © the author(s), publisher and licensee Medip Academy. This is an open-access article distributed under the terms of the Creative Commons Attribution Non-Commercial License, which permits unrestricted non-commercial use, distribution, and reproduction in any medium, provided the original work is properly cited.

### ABSTRACT

Hepatocellular carcinoma with extrahepatic metastasis are a threat to public health worldwide. Lung, bones and abdominal lymph nodes are the major sites of metastasis from liver primary, adrenal metastasis being a less common site. Here we present an old male presented with upper abdominal pain diagnosed as advanced, unresectable hepatocellular carcinoma with right adrenal metastasis. Patient was treated with multi-kinase inhibitor sorafenib and outcome was acceptable with good patient compliance.

**Keywords:** Hepatocellular carcinoma, Right adrenal metastasis, Upper abdominal pain, Sorafenib

### INTRODUCTION

For the last 50-years, hepatocellular carcinoma (HCC), the primary liver carcinoma, possess a major worldwide risk to public health. Although it is still more prevalent in developing countries; there is a recent positive growth pattern in developed countries, more so 2000 onwards, as a consequences of higher prevalence of hepatitis C infection and increase in consumption of alcohol. Further appearance of extrahepatic metastasis makes it more vulnerable. New multimodality approaches are explored in literature for advanced metastatic disease which are unresectable. Although local therapy and liver transplant are carried out in a lots of case series, targeted therapies are still the standard of care in many centres especially for inoperable, metastatic cases. Here we present an atypical case of multifocal hepatocellular carcinoma with extrahepatic adrenal metastasis treated by oral targeted agent sorafenib only.

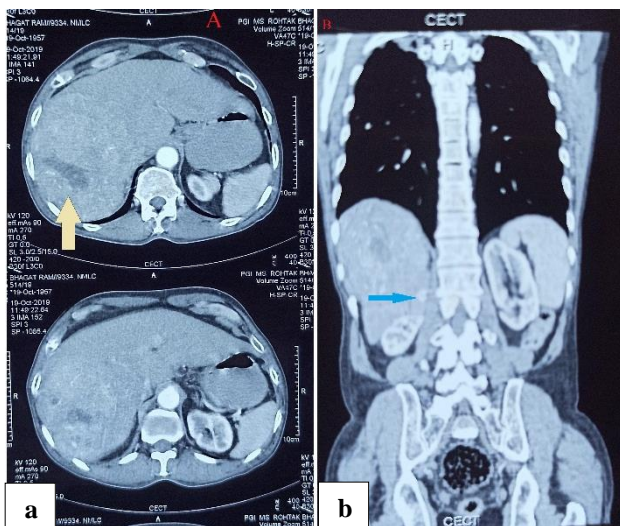
### CASE REPORT

A 62-year old male, without any other co-morbidities, presented with upper abdomen pain of 2-months duration, which was insidious in onset, dull aching in nature, mild

to moderate in intensity, gradually progressive and not radiating to any other site. It was not associated with any vomiting, altered bowel habits, or blood in stools. Patient had no associated history of fever, weight loss, anorexia, headache, chest or abdominal discomfort, pedal oedema or upper gastro-intestinal bleeding. Patient was vegetarian, non-smoker, non-alcoholic. He had a history of Koch's 30-years back, took anti-tubercular therapy for 6-months and was cured completely; no history of viral hepatitis in past. There was no history of malignancy in family members. General physical examination revealed yellow discoloration of palm and sclera i.e. jaundice, but no signs of liver cirrhosis. Per abdomen examination revealed rigid abdomen with tenderness in right hypochondrium and hepatomegaly without any signs of ascites, dilated abdominal vein or splenomegaly.

Complete hemogram and renal function test of the patient were within normal limits, but liver enzymes serum glutamic oxaloacetic transaminase (SGOT) and serum glutamic pyruvic transaminase (SGPT) and bilirubin (both direct and indirect) were elevated. All the relevant viral markers like hepatitis-B (HBV), hepatitis-C (HCV) and human immuno-deficiency virus (HIV) were negative, but alpha-fetoprotein (AFP) was severely raised having initial

value of 412 ng/ml. A chest radiograph did not indicate any metastatic nodules. Contrast enhanced computed tomography (CECT) of the abdomen region revealed hepatomegaly with large well circumscribed lesion of size 12.1×10.1×10.7 cm in the right lobe of liver with central scarring and multiple ill-defined hypodense lesions in right lobe of liver largest measuring 3.9×2.9 cm in segment VII (Figure 1a). CECT abdomen further revealed soft tissue mass measuring 3.9×1.8 cm at right adrenal gland (Figure 1b) and multiple centimeter sized lymph nodes in periportal, peripancreatic and paraaortic region. Ultrasound guided fine needle aspiration from liver mass revealed singly dispersed atypical cells with high mitotic activity, prominent multiple nucleoli and inter nuclear inclusions in a background of large numbers of benign hepatocytes. The gross pathological appearance and cytological features of the biopsy tissue confirmed it to be hepatocellular carcinoma with computed tomography (CT) scan suggestive of right adrenal metastasis.



**Figure 1: (a) CECT abdomen showing well circumscribed heterogeneously enhancing mass lesion in right lobe of liver (white arrow) with distorted architecture of liver and central non-enhancing necrotic area measuring 12.1×10.1×10.7 cm highly suggestive of hepatocellular carcinoma, (b) it further revealed bulky right adrenal gland with heterogeneously peripherally enhancing mass (blue arrow) measuring 3.9×1.8 cm suggestive of adrenal deposits (metastasis).**

Opinion from surgeon confirmed it to be an unresectable advanced lesion. Patient was given sorafenib tablet 400 mg orally twice daily for 6-months. Post-chemotherapy contrast enhanced computed tomography scan of the abdomen region, revealed hepatomegaly with a mass lesion of size 12.5×12.8×13.7 cm in the right lobe of liver with central scarring and distorted architecture. CECT abdomen further revealed bulky right adrenal gland with a mass measuring 4.7×4.2 cm and multiple centimeter sized lymph nodes in mesentery. Although disease was progressive in size in both primary and metastatic area,

patient general condition was almost fair and no specific subjective complaints was there. Serum AFP level was also decreased with a value of 246 ng/ml after 6-months of sorafenib therapy. Patient was advised for 2nd line regimen but he refused and he continued sorafenib tablet as previous schedules. After a 14-months follow up, patient is doing better without any specific complaint and is taken tablet sorafenib on continuous basis.

## DISCUSSION

Hepatocellular carcinoma (HCC), the most frequent primary tumor of liver, has a high rate of mortality despite combine modalities approach of surgery, local and targeted therapy. There are approximately 9 lacs new liver cancer in 2020 (4.7% of total cancer incidence) having the rank of 6th most common in the list of cancer incidence.<sup>1</sup>

Different risk factors, both modifiable and non-modifiable, contribute to the development of hepatocellular carcinoma; however, in around one-third cases HCC may be crypto-genetic. Although currently HCC possesses a major global burden, there are hope in a decreasing trends of its prevalence in near future by habit modification, worldwide vaccination and other clinical measures.<sup>2</sup>

Older patients presented with abdominal pain, jaundice and weight loss should be suspicioned for the possibility of hepatocellular carcinoma. However, the alternative diagnoses always be considered, which included but not limited to liver cirrhosis, haemangioma, pancreatitis and pancreatic carcinoma, abdominal tuberculosis, cholangiocarcinoma and carcinoma gall bladder, pyogenic liver abscesses, lymphoma and obviously metastatic tumors of liver from other primary (colorectal, lung and many more). Routine blood investigations and imaging techniques are enough to distinguish some of this conditions, whereas definite testing are required in some cases. A definitive biopsy is must to conclude the diagnosis as HCC and to differentiate it from other rare tumor of liver.

A few randomized trials have proved the efficacy of sorafenib, a multi-target tyrosine kinase inhibitor, in terms of both overall survival (OS) and time to progression (TTP) in advanced HCC.<sup>3,4</sup> Although it rarely induces a complete response, sorafenib has remained the gold standard targeted agent for inoperable HCC for a long time until in 2018, lenvatinib, another multi-kinase inhibitor, also approved for same indication based on a non-inferiority trial.<sup>5</sup> Several others targeted and immunotherapy agents like regorafenib, ramucirumab, cabozantinib, nivolumab has been evaluated as second line treatment in refractory, progressive HCC with variable outcomes.<sup>2</sup>

A handful of cases of HCC presents with extrahepatic metastasis depending on the size and multicentricity of primary lesion, incidence of which is continuously increasing due to advancement in diagnostic accuracy.

Although the majority of extrahepatic metastatic sites are lung, bone and abdominal lymph nodes in most of the cases, adrenal gland metastasis was reported as high as 8.8% in a review study.<sup>6</sup> The mechanism of adrenal gland metastasis in HCC is either through direct extension or by haematogenous spread thorough retroperitoneal venous system. Prognosis of HCC with extrahepatic metastasis is depressing without any standard therapy guidelines at present. 5-year survival of HCC with extrahepatic adrenal metastasis ranges from 20 to 45% with resection of adrenal lesion being the independent index of favourable outcome.<sup>7</sup> In most of the case these lesions are unresectable and approach to such patient is done mostly with targeted therapy or best supportive care depending upon general condition of the patient. Maximum of these patients died of progressive intrahepatic tumor rather than extrahepatic lesion, and resection (debulking) of primary intrahepatic tumor, whenever feasible, has gained interest nowadays along with systemic therapy for survival benefit.<sup>8</sup>

In our patient it was demonstrated that although sorafenib did not offer response in both primary and metastatic sites, it induced subjective relief in symptoms and serum AFP level also decreased. Patient also tolerated the drug well. Though an alternative anti-HCC drug may be induced more response, due to patient refusal we choose to continue the treatment and patient is doing well.

## CONCLUSION

Although mainstay of therapy in HCC is surgical resection, it is not feasible in majority of cases due to extent of lesion. Several other treatment modalities, ranging from local therapy to radiation therapy and last but not the list liver transplantation, have been considered for effective treatment. Our own approach was to use the well-approved classic oral multi-kinase inhibitor sorafenib in a middle aged patient of HCC with right adrenal metastasis and to get an acceptable outcome with good patient compliance.

*Funding: No funding sources*

*Conflict of interest: None declared*

*Ethical approval: Not required*

## REFERENCES

1. World Health Organization International Agency for Research on Cancer (IARC). GLOBOCAN 2020: Population Fact Sheets: World. 2020. Available at: <https://gco.iarc.fr/today/fact-sheets-populations>. Accessed on 04 May 2020.
2. Marino D, Zichi C, Audisio M, Sperti E, Di Maio M. Second-line treatment options in hepatocellular carcinoma. *Drugs Context*. 2019;8:212577.
3. Rimassa L, Santoro A. Sorafenib therapy in advanced hepatocellular carcinoma: the SHARP trial. *Expert Rev Anticancer Ther*. 2009;9(6):739-45.
4. Cheng AL, Kang YK, Chen Z, Tsao CJ, Qin S, Kim JS, et al. Efficacy and safety of sorafenib in patients in the Asia-Pacific region with advanced hepatocellular carcinoma: a phase III randomised, double-blind, placebo-controlled trial. *Lancet Oncol*. 2009;10(1):25-34.
5. Yamashita T, Kudo M, Ikeda K, Izumi N, Tateishi R, Ikeda M, et al. REFLECT-a phase 3 trial comparing efficacy and safety of lenvatinib to sorafenib for the treatment of unresectable hepatocellular carcinoma: an analysis of Japanese subset. *J Gastroenterol*. 2020;55(1):113-22.
6. Uchino K, Tateishi R, Shiina S, Kanda, M, Masuzaki R., Kondo Y et al Hepatocellular carcinoma with extrahepatic metastasis. *Cancer*. 2011;117:4475-83.
7. Nugroho A, Lee KW, Lee KB, Kim HS, Kim H, Yi NJ, Suh KS. Adrenal metastasis in sequentially developed combined hepatocellular carcinoma-cholangiocarcinoma: A case report. *Ann Hepatobiliary Pancreat Surg*. 2018;22(3):287-91.
8. Mao K, Wang J. Present treatment situation of hepatocellular carcinoma with extrahepatic metastasis. *Zhonghua Wai Ke Za Zhi*. 2019;57(6):466-70.

**Cite this article as:** Paul D, Singh B, Dhankhar R, Kaushal V. Hepatocellular carcinoma with extrahepatic adrenal metastasis: an atypical case report. *Int J Sci Rep* 2021;7(7):360-2.