

## Case Report

# Primary hydatid cyst of the psoas adherent to the aortoiliac axis: a real therapeutic challenge

Anwar Rahali\*, Rahal Mssrouri, Marouane Baiss, Abderrahmane Mansouri,  
Hamid Mohamed, Jalil Mdaghri, Khalid Lahlou,  
Said Benamr, Abdellatif Settaf

Department of Hepatobiliary, Digestive and Endocrine Surgery, Department Of Surgery B, University Hospital Center, Ibn Sina, Rabat, Morocco

**Received:** 17 April 2021

**Revised:** 19 May 2021

**Accepted:** 20 May 2021

**\*Correspondence:**

Dr. Anwar Rahali,

E-mail: [rahali.anwar87@gmail.com](mailto:rahali.anwar87@gmail.com)

**Copyright:** © the author(s), publisher and licensee Medip Academy. This is an open-access article distributed under the terms of the Creative Commons Attribution Non-Commercial License, which permits unrestricted non-commercial use, distribution, and reproduction in any medium, provided the original work is properly cited.

### ABSTRACT

Hydatidosis of the psoas is an unusual entity even in countries endemic to hydatid disease. We reported a rare case of hydatid cyst of psoas in a 54 year old man without pathological history. The atypical clinical presentation and the uncharacterizable radiology have demonstrated the essential role of surgery and histological analysis in the management of this type of lesion. The patient underwent a resection of the protruding dome with drainage of the residual cavity because of the anatomical relationships of this hydatid cyst. Through this case and literature review, we aimed to discuss the diagnostic means, the natural course of the disease, the differential diagnoses as well as the therapeutic options for a hydatid cyst of the psoas.

**Keywords:** Hydatid cyst, Psoas, Diagnosis, Surgery, Case report

### INTRODUCTION

Hydatid cysts are preferentially located in the liver and lungs. They are rarely found in muscles and the reported incidence is less than 5%.<sup>1</sup> The primitive location in the psoas is unusual, only a few cases have been described in the world literature.<sup>2</sup> We reported a case of hydatid cyst of the psoas in a 54 year old patient which was surgically treated by resection of the protruding dome.

### CASE REPORT

L. F., a 54-year-old patient, without significant medical history, presented with intermittent pain and discreet swelling in the left iliac fossa, gradually increasing in size without other associated signs. Physical examination was in favor a mass measuring 10 cm in diameter, tender and

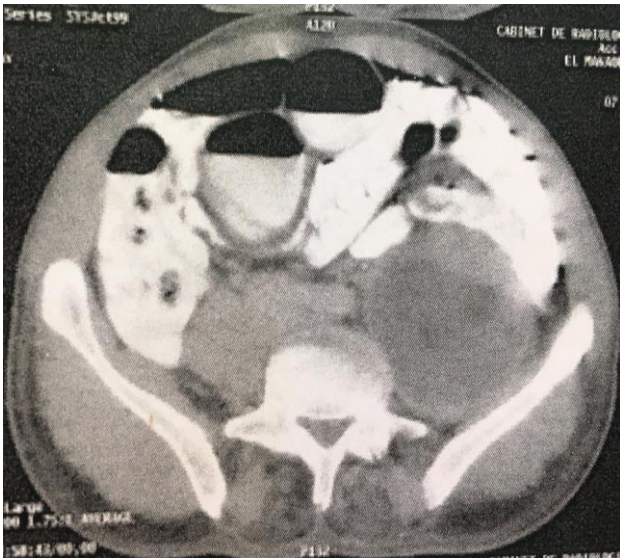
soft in the left iliac fossa extending to the left para lumbar fossa. Routine laboratory tests were without anomalies. An abdominal CT revealed a round and heterogeneous mass of the left psoas muscle extended over 14 cm in large diameter, coming into contact with the aortoiliac axis (Figure 1 and 2).

The surgical indication was therefore chosen for the management of symptomatic mass of the left psoas. After a midline infraumbilical laparotomy, per operative discovery showed a retro-peritoneal mass, oblong, solid, encapsulated, located on the posterior face of the left psoas muscle and making intimate contact with the aortoiliac axis without separation plane (Figure 3). A puncture of the mass brought back hydatid material. A resection of the protruding dome with drainage of the

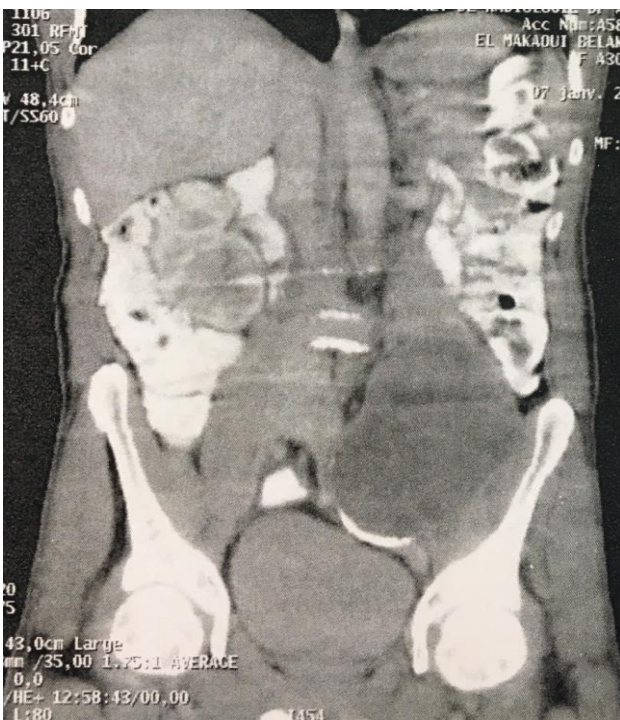
residual cavity was performed because of the anatomical relationships of this hydatid cyst (Figure 4 and 5).

The histological analysis was in favor of a hydatid cyst including scolices and specific pathogens without histological signs of malignancy.

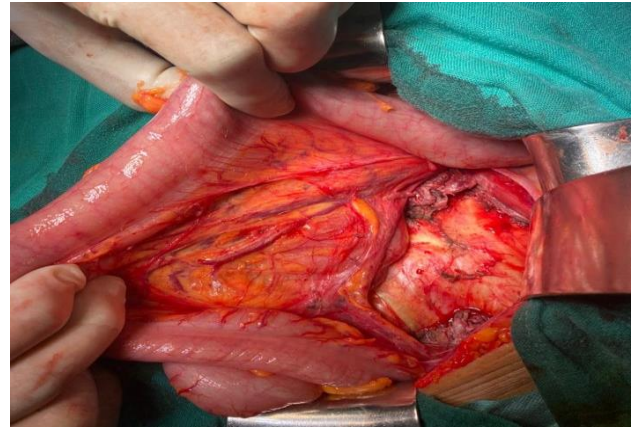
The post-operative surveillance was without abnormalities, the patient was placed under oral albendazol for 6 months with periodic control of liver enzyme tests.



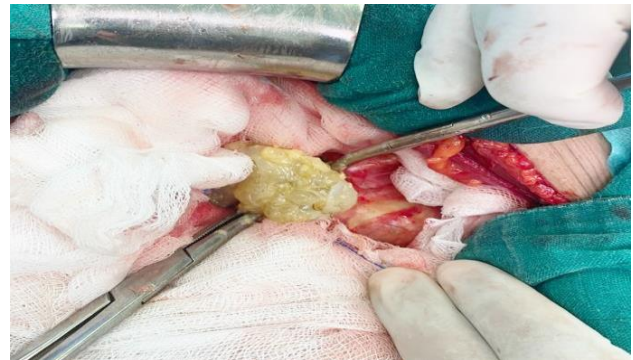**Figure 1: Transverse CT scan showing the hydatid cyst of the psoas.**



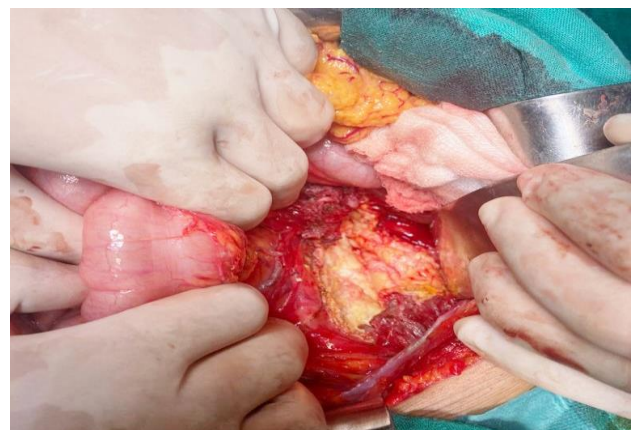**Figure 2: Coronal CT scan showing the hydatid cyst in direct contact with the aortoiliac axis.**



**Figure 3: Intraoperative image showing the location of the hydatid cyst on the posterior surface of the left psoas muscle.**



**Figure 4: Intraoperative image showing the proliferous membrane and daughter vesicles of the hydatid cyst.**



**Figure 5: Intraoperative image showing the residual cavity after resection of the protruding dome.**

## DISCUSSION

Echinococcosis is a cosmopolitan anthroponozoonose affecting mainly people living in rural areas. The dogs are the definitive hosts. Humans are an accidental intermediate host who become infected either directly



through contact with dogs or indirectly through ingesting food contaminated by animal excreta.<sup>3</sup>

More than 80-90% of hydatidosis occurs in the liver, lungs, or both.<sup>4</sup> The location at the psoas muscle is rare, constituting 3% of all muscle locations.<sup>5</sup> This rarity is justified by the role of hepatic and pulmonary barriers which oppose the migration of hydatid into systemic circulation.<sup>6</sup>

The clinical presentation of hydatid cyst of the psoas is atypical. Usually, it is a well-defined, renitent and firm iliac or lumbar mass. Some cases can be revealed by complications such as superinfection or compression syndrome.<sup>7</sup> In our case, the patient presented with pain and swelling in the left iliac fossa with a mass in physical examination.

Hydatid serology confirms the diagnosis when it is positive. However, there are a lot of false negatives estimated at 80%. Hypereosinophilia is not specific. It is found in all parasitosis.<sup>8,9</sup>

Ultrasonography represents the first line examination with an estimated 96% reliability. It characterizes the evolutionary stages of the Gharbi classification.<sup>5,10</sup>

In deep locations such as the psoas, the CT has a diagnostic value for a precise topography. In our case, CT revealed a mass of the left psoas muscle in direct contact with the aortoiliac axis. MRI is exceptionally used to assess the vitality of cyst by revealing the hypersignal in daughter vesicles on T2 sequences.<sup>11</sup>

The differential diagnosis of muscular hydatid cyst is very large, it includes mainly: lipoma, calcified hematoma, abscess and benign or malignant tumor.<sup>7</sup>

The treatment of hydatid cyst of the psoas is surgical. A complete en-bloc-resection of the cyst with total pericystectomy is the ideal procedure, but it is not always practicable, especially when the cyst is deep or in contact with vessels.<sup>12</sup> In our case, we performed aspiration of the cyst with resection of the protruding dome due to the contact with the aortoiliac arterial axis. Medical treatment with albendazole is reserved for inoperable patients or local recurrences in conjunction with surgery.<sup>5</sup> It is used with an adult dosage of 400 mg orally, twice a day and a pediatric dosage of 15 mg/kg/day (maximum of 800 mg) for 1 to 6 months.<sup>4</sup>

## CONCLUSION

Hydatid cyst of the psoas is an unusual location even in countries endemic to hydatidosis. Its diagnosis is quite difficult, especially since some cysts cannot be

characterized on radiological imaging. Surgical treatment and histological analysis provide a certain diagnosis and a lasting disappearance of the lesion.

*Funding: No funding sources*

*Conflict of interest: None declared*

*Ethical approval: Not required*

## REFERENCES

1. Erol B, Onay T, Caliskan E, Okay E. Oncological approach with antihelminthic chemotherapy and wide resection in the treatment of musculoskeletal hydatidosis. A review of 10 cases with mean follow-up of 64 months. *Acta Orthop Belg.* 2015;81(3):530-7.
2. Melis M, Marongiu L, Scintu F, Pisano M, Capra F, Zorcolo L, et al. Primary hydatid cysts of psoas muscle. *ANZ J Surg.* 2002;72(6):443-5.
3. Dumon H, Quilici M. Hydatid disease: parasitology, epidemiology and prophylaxis. *Rev Prat.* 1978;28(37):2827-34.
4. Sachar S, Goyal S, Goyal S, Sangwan S. Uncommon locations and presentations of hydatid cyst. *Ann Med Health Sci Res.* 2014;4(3):447-52.
5. Ossibi PE, Yazough I, Abdul-Razak S, Oudou AAZ, Majdoub KI, Toughrai I, et al. Hydatid cyst of the psoas: a rare location. *Surg Sci.* 2015;6:123-5.
6. Soufi M, Lahlou MK, Messrouri R, Benamr S, Essadel A, Mdaghri J, et al. Kyste hydatique du psoas: à propos de deux cas. *J Radiol.* 2010;91(12):1292-4.
7. ElMalki HO, ElMejdoubi Y, Bouslami B. Kyste hydatique du muscle psoas. *Cahiers Santé.* 2007;17(3):177-9.
8. Rahali A, ElMouhafid F, ElBrahmi Y, Ali AA. Hepatic cyst: what diagnosis? *Int Surg J.* 2020;7:4184-7.
9. Makni F, Hachicha L, Maeddi F, Hammami H, Cheikhrouhou F, Sellami H, et al. Contribution of Western blotting to the diagnosis of hydatidosis. *Bull Soc Pathol Exot.* 2007;100(3):171-3.
10. Gharbi HA, Hassine W, Branner MW. Ultrasound examination of hydatid liver. *Radiology.* 1981;139(2):459-63.
11. García-Díez AI, Mendoza LHR, Villacampa VM, Cózar M, Fuertes MI. MRI evaluation of soft tissue hydatid disease. *Eur J Radiol* 2000;10(3):462-6.
12. Mseddi M, Dahmene MM. Kyste hydatique musculaire. *Rev Chir Orthop reparatrice Appar Mot* 2005;91:267-71.

**Cite this article as:** Rahali A, Mssrouri R, Baiss M, Mansouri A, Mohamed H, Mdaghri J, et al. Primary hydatid cyst of the psoas adherent to the aortoiliac axis: a real therapeutic challenge. *Int J Sci Rep* 2021;7(7):363-5.