

## Case Report

# Broad ligament hematoma after normal vaginal delivery: a rare case scenario

Mequanent T. Adow<sup>1\*</sup>, Nebso G. Gechu<sup>2</sup>, Dereje T. Eshete<sup>3</sup>, Amanu G. Siraneh<sup>4</sup>

<sup>1</sup>Department of Obstetrics and Gynecology, College of Health Science, Debretabor University, Debretabor, Ethiopia

<sup>2</sup>Department of Obstetrics and Gynecology, College of Health Science, Arbaminch University, Arbaminch, Ethiopia

<sup>3</sup>Department of Obstetrics and Gynecology, <sup>4</sup>Department of Clinical Anaesthesia, College of Medicine and Health Science, Hawassa University, Hawassa, Ethiopia

**Received:** 21 April 2021

**Accepted:** 12 May 2021

### \*Correspondence:

Dr. Mequanent T. Adow,

E-mail: [mequanent.tariku@gmail.com](mailto:mequanent.tariku@gmail.com)

**Copyright:** © the author(s), publisher and licensee Medip Academy. This is an open-access article distributed under the terms of the Creative Commons Attribution Non-Commercial License, which permits unrestricted non-commercial use, distribution, and reproduction in any medium, provided the original work is properly cited.

### ABSTRACT

Broad ligament hematoma is a very rare complication following normal vaginal delivery. This article reports broad ligament hematoma following normal vaginal delivery in a 25 years old para 2 still birth 1 woman after 3 hours of delivery. Based on clinical and transabdominal ultrasound examination broad ligament hematoma was diagnosed. She was on conservative management for 36 hours after confirming the diagnosis. Later, she developed symptoms of anemia and transabdominal ultrasound showed expanding hematoma and minimal hemoperitoneum. Surgical intervention decided and total hysterectomy was performed.

**Keywords:** Broad ligament hematoma, Hysterectomy, Normal vaginal delivery, Uterine artery ligation

### INTRODUCTION

Pelvic hematoma which is collection of blood above levator ani is termed as broad ligament or supralelevator hematoma. Broad ligament hematoma following normal vaginal delivery is a very rare event. Huge amount of hematoma collection can occur between the folds of broad ligament extending to natural cleavage lines of connective tissue before developing shock. Hence high index of suspicion is needed in patients with manifestations of postpartum hemorrhage with no or minimal vaginal bleeding that can occur during delivery, just after delivery or later in the puerperium.

### CASE REPORT

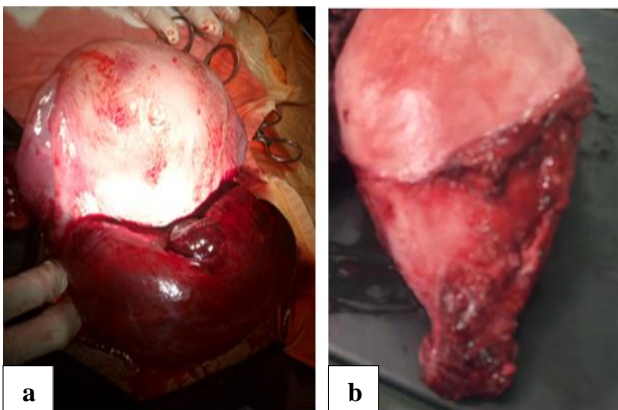
This was a 25 years old para 2, stillbirth 1 at 9 hour postpartum referred from government primary hospital after delivery with diagnosis of hypovolumic shock due to suspected uterine rupture. She was induced for term prelabor rupture of membrane and delivered vaginally a

3000 gram neonate with good Apgar score. Her first stage of labor lasted for 10 hours and second stage 1 hour. No episiotomy or instrumental delivery performed and placenta managed actively. Three hours after delivery she developed intermittent minimal vaginal bleeding, abdominal pain, easy fatigability, dizziness and her vitals start to deteriorate. She was resuscitated with two liters of normal saline, transfused one unit of whole blood and referred to our tertiary center for better evaluation and management. At admission, patient was acutely sick looking, conscious with pulse 120 beats per minute (bpm) and blood pressure (BP) of 110/60 mmHg. She had pale conjunctiva and 24 week sized well contracted uterus. There was 16 week sized, tender anterior uterine wall mass. Genital examination revealed no vulvar or vaginal swelling, active vaginal bleeding or lower genital tract laceration. Immediately after admission hematocrit (hct) was 25% (Hgb=7.4 mg/dl), platelets=225,000, blood group and Rh=A+, prothrombin time (PT) and activated partial thromboplastin time (aPTT) in normal limit. Transabdominal ultrasound showed 8×6 cm hypoechoic

mass on lower uterine segment extending to right broad ligament. Broad ligament hematoma was considered and expectant management planned. The plan was to follow her pulse rate, respiratory rate, blood pressure, urine output and serial Hct. She was started on ampicillin 2 gm IV QID and metronidazole 500 mg IV TID. She was also transfused additional 2 units of whole blood. Her blood pressure and urine output was normal throughout follow up and pulse rate ranges from 104-116 bpm. The serial hct was 25%, 29%, 30%, 32%, 31%, 27% and 22% at 1, 6, 12, 18, 24, 30 and 36 hours of admission respectively. At 36 hours of admission she was also complaining easy fatigability, light headedness and become pale with pulse rate of 122 bpm. At this time the repeated transabdominal ultrasound showed increasing hematoma (10×8 cm) and minimal hemoperitoneum. Considering expanding broad ligament hematoma emergency laparotomy decided.

Informed consent was taken and under general anesthesia with midline vertical incision abdomen entered. Intraoperatively there was about 300 ml hemoperitoneum, 12×9 cm hematoma on anterior lower uterine segment extending more to right broad ligament. Hemoperitoneum sucked out and hematoma evacuated.

There was about 5 cm superficial vertical tear with no communication to endometrium or cervical canal. The tear extends down to the cervix which was bleeding and ligated. There was also multiple oozing from surface not responding for compression for which unilateral uterine artery and ovarian artery ligation tried. There was technical difficulty for internal iliac artery ligation. Finally total hysterectomy was done and received additional two units of whole blood post operatively. She was fully recovered and discharged on 6<sup>th</sup> post-operative day.



**Figure 1: (a) Broad ligament hematoma occupying anterior uterine wall and, (b) uterus with cervix after total hysterectomy.**

## DISCUSSION

Broad ligament hematoma following normal vaginal delivery is a rare complication. Incidence of puerperal hematoma was cited as to be 1/309 to 1/1500 and large

hematoma as 1/4000 vaginal deliveries but has not specified incidence of supravaginal hematoma.<sup>1</sup> In one study done in 2009, broad ligament hematoma was found to be 1/20,000 vaginal deliveries.<sup>2</sup> Puerperal hematoma can be classified as vulvar, vulvovaginal, paravaginal and retroperitoneal hematoma or as vulvar, vaginal, vulvovaginal and subperitoneal.<sup>1,3</sup> Broad ligament hematoma can be seen during cesarean delivery due to lacerations to branches of uterine or vaginal vessels.<sup>1</sup> It can also follow precipitated labor, instrumental delivery, delivery of multiples, prolonged second stage, vigorous uterine massage, birth weight above 4000 grams, coagulation abnormality.<sup>4,6</sup> Broad ligament hematoma following spontaneous vaginal delivery follows mainly uterine rupture. But can happen due to cervical tear extending to lower uterine segment or the exact cause for the hematoma may not be elucidated.<sup>1,2</sup> In our case the superficial vessel tear may be attributed. Fifty percent can be recognized immediately while the rest are discovered subacutely after 24 hours of delivery.<sup>2</sup> Clinical presentation includes postpartum lower abdominal or perineal pain together with shock, elevated uterine fundus, unilateral fluctuating mass, urge to defecate, and inability to pass urine.<sup>7,8</sup>

Ultrasound is not helpful for small sized broad ligament hematoma rather magnetic resonance imaging (MRI) is recommended.<sup>9</sup> But large sized broad ligament hematoma like in our case can be diagnosed with clinical feature and ultrasound.

Broad ligament hematoma can be managed conservatively or surgically depending on patient's hemodynamic status, size and rate of hematoma expansion. Hemodynamically stable patient with small size non expanding hematoma can be managed expectantly. However, hemodynamically unstable or patients with expanding hematoma needs resuscitation followed by laparotomy. Our case initially was stable except tachycardia and expectant management was tried with strict follow up. But later she developed hemodynamic instability and expanding hematoma, for which, she undergo laparotomy. Preserving her fertility with compression of bleeding site or uterine and ovarian artery ligation was not successful. Finally total hysterectomy performed. Internal iliac artery ligation or angiographic embolization has been proposed as options of surgical management depending on clinical condition of a patient.<sup>1,5</sup>

## CONCLUSION

Broad ligament hematoma is a rare complication after spontaneous vaginal delivery. High degree of suspicion for supravaginal hematoma is needed in maternal collapse with minimal or no obvious vaginal bleeding. Clinically stable patients with non-expanding broad ligament hematoma can be managed conservatively. Close follow up is needed since expansion of hematoma and clinical deterioration like in our case occurs as late as 45 hours of delivery or 36 hours of confirmed diagnosis of hematoma.

## ACKNOWLEDGEMENTS

Authors would like to thank the client who gave us her consent to publish her condition.

*Funding: No funding sources*

*Conflict of interest: None declared*

*Ethical approval: Not required*

## REFERENCES

1. Bhansakarya R, Subedi S. Broad Ligament Hematoma Following Vaginal Delivery—A Rare Entity. J Nobel Med Coll. 2019;8(1):63-5.
2. Saleem N, Ali HS, Irfan A, Afzal B. Broad ligament haematoma following a vaginal delivery in primigravida. Pak J Med Sci. 2009;25(4):683-5.
3. Cunningham F, Leveno KG. Williams obstetrics. 24th edition. McGraw-Hill Education. 2014.
4. Edmonds K. Dewhurst's textbook of obstetrics and gynaecology for postgraduates. Wiley-Blackwell. 1999.
5. Bankada V, Purra P, Ningappa AM, Jirankal S. A Rare Case of Bilateral Broad Ligament Haematoma in Twin Pregnancy. J Clin Diagn Res. 2015;9(10):QD03-5.
6. Murali R, Hosni M, Navaneetham N. A Rare Case of Broad Ligament Haematoma 24 Hours after Normal Vaginal Delivery. J Clin Case Rep. 2014;4(7):391.
7. Yalla D, Nadar AN, Rani GU. Spontaneous broad ligament haematoma following a normal vaginal delivery: a case report. Int J Reprod Contracept Obstet Gynecol. 2011;7(6):2522.
8. Kovo M, Eshed I, Malinger G. Broad ligament hematoma following a normal vaginal delivery. Gynecol Surg. 2006;3(2):138.
9. Jain KA, Olcott EW. Magnetic resonance imaging of postpartum pelvic hematomas: early experience in diagnosis and treatment planning. Magnetic Resonance Imaging. 1999;17(7):973-7.

**Cite this article as:** Adow MT, Gechu NG, Eshete DT, Siraneh AG. Broad ligament hematoma after normal vaginal delivery: a rare case scenario. Int J Sci Rep 2021;7(7):366-8.